

# Analysis of Mast Cells Counts in Different Histopathological Grades of Leukoplakia and Squamous Cell Carcinoma of Oral Cavity

Kishor Patil

## ABSTRACT

**Aim and objective:** The aim and objective of this study was to estimate mast cell (MC) count in histopathological dysplasia grades in oral leukoplakia (OL) patients and in histopathological grades in oral squamous cell carcinoma (OSCC) patients and thereby determining their possible role in these lesions pathogenesis.

**Materials and methods:** Forty histopathologically confirmed cases of OL and OSCC were taken. Sections of 4 microns thickness were taken from each paraffin block and stained with 1% standard toluidine blue stain for demonstrating MCs. Counting of MCs was done by 3 observers using a 10× eyepiece fitted with 1 cm<sup>2</sup> graticule and 40× objectives in 10 different fields in each slide.

**Results:** It was found that the MC count was higher in OSCC than OL and control group and the difference was found to be statistically significant. (One way Analysis of Variance test) Also, the MC count increased from mild to severe dysplasia in OL patients, as well as from well to poorly differentiated grades in OSCC patients ( $p < 0.01$ ).

**Conclusion:** This study indicates that MC count was increased from mild to moderate to severe dysplasia of OL patients and also from well differentiated (WD) to moderately differentiated (MD) to poorly differentiated (PD) grades of OSCC patients.

**Clinical significance:** MC count was increased in higher grades of epithelial dysplasia in OL patients and higher grades in OSCC patients.

**Keywords:** Mast cells, Oral leukoplakia, Oral squamous cell carcinoma.

*World Journal of Dentistry* (2021): 10.5005/jp-journals-10015-1795

## INTRODUCTION

Mast cells (also called as labrocytes or mastocytes) are large connective tissue cells. They are usually present near the capillaries and contain numerous basophilic granules in their cytoplasm, because of which the nucleus may be obscured. MC was discovered first by Paul Ehrlich in 1878 and he used the word "Mastzellen" to illustrate these cells which is a German term referring to "a well fed cell". Ehrlich had shown the relation of MCs with inflammation, blood vessels and with neural tissue. Thus, MCs are at present known as strong effector cells of the immune system.<sup>1,2</sup>

MCs with approximately 12 μ diameter are of varied shapes (round, spindle or oval) and are crowded with 50–100 granules. Normally the life span of MC is weeks to months. MC discharge preformed mediators such as histamine, tryptase, heparin, lipid derived mediators [leukotrienes B<sub>4</sub> (LTB<sub>4</sub>), LTC<sub>4</sub>, LTD<sub>4</sub> and LTE<sub>4</sub>], mitogenic cytokines (IL-3 and IL-5), prion β inflammatory cytokines (IL-1 and TNF-α) and immunomodulatory cytokines (IL-4 and IL-10).<sup>3</sup>

MCs by release of their mediators can have a considerable role in transformation of OL into invasive OSCC. Previous literature shown that the enhanced MC accumulation is related to poor prognosis in a variety of tumors and thereby demonstrating a biological role of MCs in progression of tumors.<sup>4</sup>

This study was done to estimate MC count in mild, moderate and severe histopathological grades of OL and WD, MD and PD histopathological grades of OSCC patients and thereby determining possible role of MC in the pathogenesis of these lesions.

Department of Oral Pathology and Microbiology, SMBT Dental College and Hospital, Sangamner, Maharashtra, India

**Corresponding Author:** Kishor Patil, Department of Oral Pathology and Microbiology, SMBT Dental College and Hospital, Sangamner, Maharashtra, India, Phone: +91 8600828296, e-mail: drpatilkishor1@gmail.com

**How to cite this article:** Patil K. Analysis of Mast Cells Counts in Different Histopathological Grades of Leukoplakia and Squamous Cell Carcinoma of Oral Cavity. *World J Dent* 2021;12(1):74–77.

**Source of support:** Nil

**Conflict of interest:** None

## MATERIALS AND METHODS

The study was conducted in the oral pathology department at SMBT dental college, Sangamner. The patients were selected from the OPD of the department. Firstly, the patients clinically having leukoplakia and malignant ulcer were taken and their histopathological study was done using H and E staining after doing biopsy of the lesional site.

Secondly, out of these, forty histopathologically confirmed cases each of OL (showing epithelial dysplasia) and OSCC (showing invasion of tumor cells into connective tissue) were taken. Ten tissues were taken as controls which were removed during third molar extractions or they were gingival tissues obtained after mobile tooth extractions. The cases of OL were classified into hyperkeratosis with mild dysplasia, moderate dysplasia and severe

dysplasia according to histopathological findings. Also OSCC were histopathologically classified into WD, MD and PD.

### Inclusion Criteria

- In patient with clinical findings of oral leukoplakia, only cases showing epithelial dysplasia on histopathological finding were taken into consideration.
- Histopathologically confirmed cases of OSCC.

### Exclusion Criteria

- Leukoplakia cases which were histopathologically showing break in the basement membrane (Microinvasive carcinoma).
- Oral squamous cell carcinoma variants were excluded.

The section of 4–6 microns thickness taken from each paraffin block and stained with 1% standard toluidine blue stain for demonstrating MCs. MC counting was done using a 10× eyepiece fitted with 1 cm<sup>2</sup> graticule and 40× objectives in 10 different fields in each slide. The MC counting was done by three different observers and the mean of 3 observations were taken. The MCs were seen as purple cells with irregular outline, central placed nucleus and granular cytoplasm in toluidine blue stain (Figs 1 and 2).

### Statistical Analysis

The relation of MC counts of mild to moderate to severe dysplasia in OL patients evaluated with the help of one-way analysis of variance test, using IBM SPSS statistics version 16. Similarly association between MC counts of WD to MD to PD OSCC was evaluated with one-way analysis of variance test. The diversity among the different grades was evaluated using Tukey's test for both OL and OSCC.

## RESULTS

The presented study consisted of 40 patients with OL in clinical diagnosis and histologically showing epithelial dysplasia. Also 40 patients of OSCC on clinical diagnosis and which were histopathologically confirmed. In OL, the patients were in the age range of 32–67 years, while in OSCC patients the age range was from 39 to 71 years. In the present study, the most common site of OL was found to be buccal mucosa, followed by tongue. In OSCC, the most common site was found gingiva, followed by lips. On clinical

diagnosis, homogeneous OL was found more common than non-homogeneous OL and in non-homogeneous type, speckled OL showed higher grades of dysplasia in histopathology.

On comparison of MC count between control group, OL group and OSCC group, the count was found more in OSCC ( $9.34 \pm 1.82$ ) as compared to OL ( $2.32 \pm 1.71$ ) and the count in OL was more as compared to control group ( $5.18 \pm 1.23$ ) and both the differences was found to be statistically significant (One way Analysis of Variance test,  $p < 0.01$ ) (Table 1).

When the MC count was compared in epithelial dysplasia grades using one-way analysis of variance test, highly significant increase was seen of the MC count from mild ( $3.22 \pm 0.43$ ) to moderate ( $5.34 \pm 0.70$ ) and from moderate to severe dysplasia ( $6.98 \pm 1.33$ ).

Also, on comparison of MC count in grades of OSCC, the count was seen increased from WD ( $7.63 \pm 1.74$ ) to MD ( $9.34 \pm 1.67$ ) and from MD to PD ( $11.07 \pm 2.06$ ) OSCC and it was statistically significant. (One way Analysis of Variance test,  $p < 0.01$ ) (Tables 2 and 3, Figs 3 and 4).

Also the MC count was compared in-between epithelial dysplasia groups by means of Tukey's test and shown a highly significant variation among mild to moderate, moderate to severe and mild to severe dysplasia in OL patients ( $p < 0.01$ ).

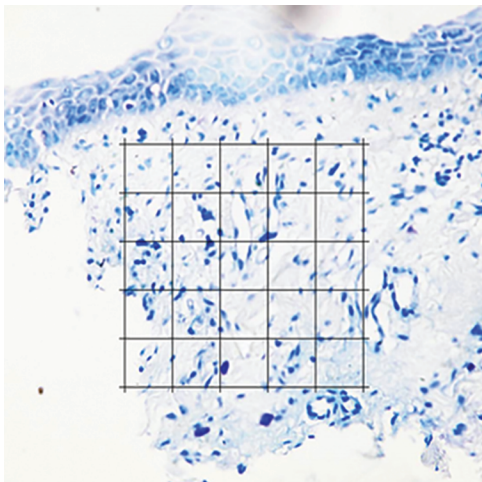
Also, MC count was compared between grades of OSCC and found a highly significant difference from WD to MD, MD to PD and WD to PD OSCC (Tukey's test,  $p < 0.01$ ) (Tables 4 and 5).

Thus it shows that there was increase in the count of MCs as increase in dysplasia grade in OL patients and also MC count increased from WD to PD OSCC patients.


## DISCUSSION

Oral cavities malignant tumors are a very serious public health concern worldwide and most common being OSCC accounting for nearly 90–95% of all oral cancers. It is an invasive and aggressive malignant epithelial tumor. Often it is preceded by development of potentially malignant disorders which histologically shows epithelial dysplasia. The important potentially malignant disorders affecting the oral cavity are OL.<sup>4</sup>

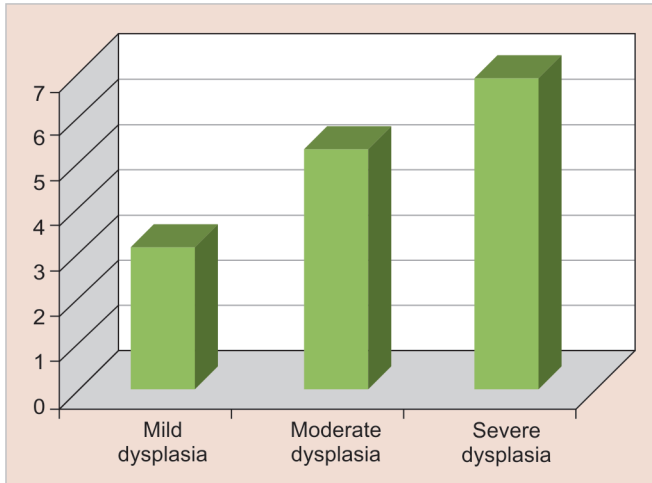
For the observation and study of MCs in histological sections various techniques were used, such as alcian blue with safranin, toluidine blue and immunohistochemistry.<sup>5</sup>



**Fig. 1:** MCs in the connective tissue in patients of OL (Toluidine blue stain, 40×)



**Fig. 2:** Presence of MCs in increased number in the deeper connective tissue of OSCC patient (Toluidine blue stain, 40×)



**Fig. 3:** Graph showing increasing MC count in OL as the grades of dysplasia increases:-

**Table 1:** Evaluation of MC count in control, OL and OSCC (One-way analysis of variance test)

Oral lesion	N	Mean $\pm$ SD	F value	p value
Control	10	2.32 $\pm$ 1.71	16.98	<0.01 (Highly significant)
Oral leukoplakia	40	5.18 $\pm$ 1.23		
Oral squamous cell carcinoma	40	9.34 $\pm$ 1.82		

SD, standard deviation

**Table 2:** Evaluation of MC count in OL (One-way analysis of variance test)

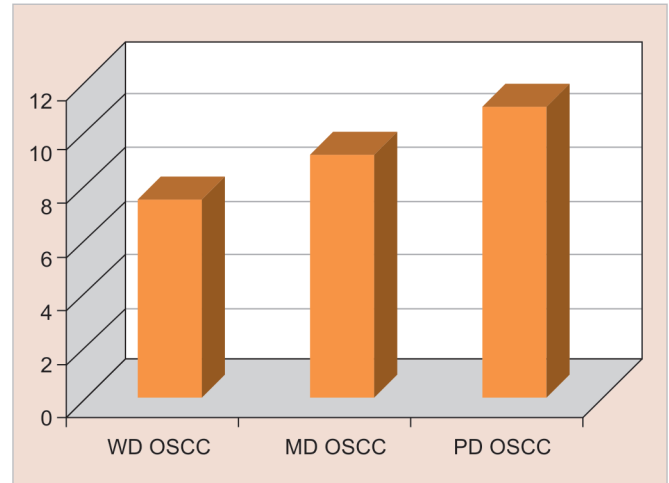
Epithelial dysplasia grades	N	Mean $\pm$ SD	F value	p value
Mild	20	03.22 $\pm$ 0.53	50.21	<0.01
Moderate	14	05.34 $\pm$ 0.70		
Severe	06	06.98 $\pm$ 1.33		

**Table 3:** Evaluation of MCs in SCC of oral cavity (One-way analysis of variance test)

OSCC grades	N	Mean $\pm$ SD	F value	p value
WD	16	07.63 $\pm$ 1.74	128.72	<0.01
MD	16	9.34 $\pm$ 1.67		
PD	08	11.07 $\pm$ 2.06		

In the present study, toluidine blue was used and on staining with this metachromatic dye, the MCs visual detection become clear and secretory granules of MCs shows peculiar metachromatic staining pattern. Thus this can be more reliable technique for the same.<sup>6-8</sup> In the current study, the accuracy of this methods was also strengthened by the insignificant interobserver variation.

MCs are present normally in the connective tissue. In general, in the skin and oral mucosa MCs are located near to the blood vessels. MCs are known to release potent mediators exerting their influence on the tissues and thereby play an important role in both oral physiologic and pathologic conditions. In lichen planus of oral cavity, MCs thought to be involved in T-lymphocytes recruitment to the sub-epithelial zone. While, in oral submucous fibrosis, MCs



**Fig. 4:** Graph showing increasing MC count in OSCC as the grades of carcinoma increases

**Table 4:** Difference between MC counts in various groups of OL (Tukey's test)

Group (I) (dysplasia)	Group (J) (dysplasia)	(I-J) Mean difference	p value
Mild	Moderate	2.12	<0.01
Mild	Severe	1.692	<0.01
Moderate	Severe	1.101	<0.01

**Table 5:** Evaluation of the MC count among groups of SCC of oral cavity (Tukey's test)

Group (I)	Group (J)	(I-J) Mean difference	p value
WD	MD	2.146	<0.01
WD	PD	5.892	<0.01
MD	PD	3.639	<0.01

through release of interleukin-1, causes augmented fibroblastic reaction.<sup>9</sup>

The tumor microenvironment alteration produce changes in MC migration, distribution in tissue and its activation. Tumor induced cytokines and chemoattractants control migration and maturation of the MC progenitors. The stem cell factor induced by cancer cells along with their receptor c-kit characterizes for the most potent and significant MC chemotaxis and migration.<sup>10</sup>

The mediators from the MC acts at different steps of angiogenesis like migration and proliferation of endothelial cells, synthesis of new vessels and mobilization of pericytes. Also MC indirectly act by activation of MMPs, which degrades the extracellular matrix (ECM).<sup>10,11</sup>

On the other side, few researchers also discovered the anti-tumor activities of MC like cytotoxic functions and release of anti-cancer compounds.<sup>11</sup>

The present study shows that there was increased MC count from control to OL and from OL to OSCC patients. The results of current study were similar to the results by Ankle et al.,<sup>7</sup> Iamaroon et al.,<sup>12</sup> and Michailidou et al.,<sup>6</sup> Rakesh et al.,<sup>4</sup> and Biviji et al.<sup>13</sup> Also opposite results of decrease of MC counts in oral dysplasia as compared to normal tissue was also recorded in study by Jandinski et al.<sup>14</sup>

In study by Rakesh et al.,<sup>4</sup> total and degranulated mean MC count was observed to be higher in OL (subepithelial, intermediate and deeper zones) as compared to normal buccal mucosa.

Biviji<sup>13</sup> found similar result in study of MC count in leukoplakia and concluded that chemical mediators (interleukin-1) in MCs causes inflammatory reaction resulting in increased epithelial proliferation seen in leukoplakia.<sup>15,16</sup>

The MCs present in the periphery of the tumor which is now confirmed by several investigators was reported first by Westple et al. in 1981.<sup>7,17</sup>

Also, the MC count increased as the dysplastic grade increases in histopathology of OL and increased from WD to PD OSCC. As per our knowledge, this is unique study where MC count was done in different grades of oral epithelial dysplasia in histopathology of OL and WD, MD and PD grades of OSCC.

MCs were found at areas of intense vascularization (called as "hot spots"), near areas of new capillary development and around the tumor margins. Recent literature suggests that the gathering of MCs in sites of the tumor margins and release of potent pro-angiogenic and angiogenic factors may symbolize a tumor-host interaction which perhaps favors tumor progression.<sup>18-20</sup>

The study was done in different grades of epithelial dysplasia in OL and different grades of OSCC patients and in each category small sample size was there. Also the sample size was still more less in the severe dysplasia grade in OL patients and PD grade in OSCC patients. Also, in the present study, only OL was taken from the premalignant lesions and conditions. Therefore, in future such type of studies including large number of patients with different premalignant lesions and conditions is needed.

## CONCLUSION

MC count was found to be increased from control to OL and from OL to OSCC. Also, there was increase in MC count as the increase in histopathological grade of dysplasia in OL and increasing grades in OSCC patients. Our observations indicate that MCs through release of variety of mediators have regulatory function on angiogenesis and inflammation may facilitate the transformation of OL into invasive OSCC.

## REFERENCES

1. Spoorthi BR, Vidya GS. Mast cell count analysis in oral inflammatory lesions, potentially malignant disorders and oral squamous cell carcinoma. *Int J Sci Res Publicat* 2013;3(12):1-4.
2. Weller CL, Collington SJ, Williams T, et al. Mast cells in health and disease. *Clin Sci* 2011;120(11):473-484. DOI: 10.1042/CS20100459.
3. Okayama Y, Kawakami T. Development, migration, and survival of mast cells. *Immunol Res* 2006;34(2):97-115. DOI: 10.1385/IR:34:2:97.
4. Rakesh S, Janardhanan M, Vinodkumar RB, et al. Analysis of mast cell counts in oral leukoplakia. *Oral Maxillofac Pathol* 2012;3(1):181-185.
5. Teófilo CR, Ferreira Junior AEC, Batista AC, et al. Mast cells and blood vessels profile in oral carcinogenesis: an immunohistochemistry study. *Asian Pac J Cancer Prev* 2020;21(4):1097-1102. DOI: 10.31557/APJCP.2020.21.4.1097.
6. Michailidou EZ, Markopoulos AK, Antoniadis DZ. Mast cells and angiogenesis in oral malignant and premalignant lesions. *Open Dent J* 2008;2:126-132.
7. Ankle MR, Kale AD, Nayak R. Mast cells are increased in leukoplakia, oral submucous fibrosis, oral lichen planus and oral submucous fibrosis. *J Oral Maxillofac Pathol* 2007;11(1):18-22. DOI: 10.4103/0973-029X.33959.
8. Singh S, Gupta V, Vij R, et al. Evaluation of mast cells in oral premalignant and malignant lesions: a histochemical study. *Natl J Maxillofac Surg* 2018;9(2):184-190. DOI: 10.4103/njms.NJMS\_49\_17.
9. Asboe-Hansen G. Mast cells in health and disease. *Bull N Y Acad Med* 1968;44(8):1048-1056.
10. Basha S, Monsur Hassan NM, Akhter R, et al. Emerging evidence of mast cell involvement in oral squamous cell carcinoma. *Biomed J Sci Tech Res* 2019;16(2):11954-11959.
11. Ramshridhar S, Narasimhan M. Immunohistochemical evaluation of mast cells in leukoplakia and oral squamous cell carcinoma. *J Clin Diagn Res* 2016;10(8):100-103.
12. Iamaroon A, Pongsiriwet S, Jittidecharaks S, et al. Increase of mast cells and tumor angiogenesis in oral squamous cell carcinoma. *J Oral Pathol Med* 2003;32(4):195-199. DOI: 10.1034/j.1600-0714.2003.00128.x.
13. Biviji AT. Mast cells in normal and leukoplakia of buccal mucosa. *J Indian Dent Assoc* 1973;45:189-191.
14. Jandinski JJ, Sonis S, Doku HC. The incidence of mast cells in selected oral lesions. *Oral Surg Oral Med Oral Pathol* 1972;34(2):245-248. DOI: 10.1016/0030-4220(72)90415-X.
15. Zhao ZZ, Savage NW, Sugarman PB, et al. Mast cell/T cell interactions in oral lichen planus. *J Oral Pathol Med* 2002;31(4):189-195. DOI: 10.1034/j.1600-0714.2002.310401.x.
16. Fattahi S, Hosseini SV, Emamverdzadeh P, et al. The compare number of mast cells in biopsy specimens of patients with erosive & non-erosive lichen planus. *Int J Curr Res Aca Rew* 2014;2(9):124-134.
17. Ashkavandi ZJ, Mashhadi-Abbas F, Sargolzaie S, et al. Evaluation of CD31 expression and mast cell count in dysplastic lesions and squamous cell carcinoma of the oral cavity. *Iran Red Crescent Med J* 2010;12(3):272-276.
18. Cheema VS, Ramesh V, Balamurali PD. The relevance of mast cells in oral squamous cell carcinoma. *J Clin Diagn Res* 2012;6(10):1803-1807. DOI: 10.7860/JCDR/2012/4503.2616.
19. Flier JS, Underhill LH, Galli SJ. New concepts about mast cells. *N Engl J Med* 1993;328(4):257-265. DOI: 10.1056/NEJM199301283280408.
20. Walsh LJ. Mast cells and oral inflammation. *Crit Rev Oral Biol Med* 2003;14(3):188-198. DOI: 10.1177/154411130301400304.