

An Unusual Multicystic Case in a Non-syndromic Patient: A Case Report

¹Briguglio Francesco, ²Briguglio Roberto, ³Falcomatà Domenico

ABSTRACT

Aim: The aim of the article is to describe an unusual case of a non-syndromic patient affected by three follicular cysts in the mandible and then by an inflammatory cyst. Furthermore, we describe two different surgical approaches that we have used to manage this case: marsupialization and enucleation.

Background: Dentigerous cysts are usually solitary cyst, the presence of multiple cysts is often combined with systemic diseases such as mucopolysaccharidosis, cleidocranial dysplasia, and basal cell nevus syndrome. They are the second cysts in order of frequency. Because of the lack of symptoms, their diagnosis is frequently radiological, and it can be suspected by the failure of tooth eruption.

Case description: Two bilateral cysts of the third lower molars and radicular cyst of the right second lower molar were treated. An excisional therapy for the two dentigerous neoformations was performed. While, as a function of the remarkable dimensions which characterized the lesion, a conservative approach by marsupialization for 8 months before, and excision after, were chosen to solve the radicular inflammatory cyst. To preserve the patency of the cystic cavity, an acrylic obturator was used.

Conclusion: In the case of multiple dentigerous cysts, a deepen clinical and systematic examination should be done to rule out any associated syndrome. Nowadays in literature, there is not a single and significant orientation based on the results obtained from the various techniques, but this case report shows that it is possible to achieve the expected therapeutic success even if in the same patient.

Clinical significance: The case that we have described allows us to observe how a correct study of the lesions allows us to have a more accurate, safe and predictable therapeutic approach that lasts in time.

Keywords: Enucleation, Follicular cysts, Multicystic patient, Radicular cyst.

How to cite this article: Francesco B, Roberto B, Domenico F. An Unusual Multicystic Case in a Non-syndromic Patient: A Case Report. *World J Dent* 2018;9(5):423-429.

Source of support: Nil

Conflict of interest: None

BACKGROUND

Dentigerous cysts are the second most common odontogenic cysts after radicular cysts.¹ Normally patients are not symptomatic, but we should suspect the presence of the lesion when intraoral clinical examination shows: the failure of tooth eruption, malalignment or a missing tooth. Although it may interest any tooth, the lower third molar is the most frequently affected.

They usually present in the second or third decades of life and are rarely seen during childhood.²

Their frequency in the general population has been estimated at 1.44 cysts for every 100 unerupted teeth.³

The etiology is due to the detachment of the dental follicle from the crown of an unerupted tooth. Dentigerous cysts are normally solitary, the presence of multiple cysts is connected with several syndromes such as polysaccharidosis or cleidocranial dysplasia.^{4,5}

In literature, bilateral maxillary dentigerous cysts in a non-syndromic patient have been reported previously only in 22 cases.^{2,6-26}

Radicular cysts are the most frequent form of mandibular cysts. According to a systematic review of 2013 that includes 26 scientific journals from 1993 to 2011 with 18297 odontogenic cysts reported, radicular cysts represent the 54.6% of odontogenic cysts of the mandible, while dentigerous appears in the 20.6%.²⁷ They derive from epithelial residues of the enamel organ that is stimulated by a periapical infectious process from pulp or a non-vital tooth.

In this article, we are going to discuss an unusual case of a non-syndromic patient affected by three follicular cysts in the position 36, 46 and 47 of the mandible and then by an inflammatory cyst in position 47.

CASE DESCRIPTION

The patient, male of 9 years, arrived at our observation in 2001 for the evaluation of an asymptomatic cystic lesion in the right maxilla. Intraoral clinical examination showed a mixed dentition and the absence of right and left first molars and there was definite swelling in association with unerupted molars 36. Slight extraoral swelling or tenderness in relation to the mandible on the same side was noted.

The anamnesis was nonsignificant, no associated syndromes were present, a routine laboratory test was normal.

¹⁻³Department of Biomedical, Dental and Morphological and Functional Images, University of Messina; Piazza Pugliatti, Messina, Italy

Corresponding Author: Falcomatà Domenico, Department of Biomedical, Dental and Morphological and Functional Images, University of Messina, Piazza Pugliatti, Messina, Italy, Phone: 3345036000, e-mail falcomatadomenico@virgilio.it

It was performed first and second radiographic assessment (Fig. 1A), in particular, orthopantomographic reveals the presence of a thin sclerotic border surrounding the well-defined unilocular radiolucent area that was present on right side of mandible in relation to first molar 36 and similar sclerotic margin was evident even on left side of mandible in relation to element 46. The first radiolucent lesion was very large load on element 36 and smaller on element 46.

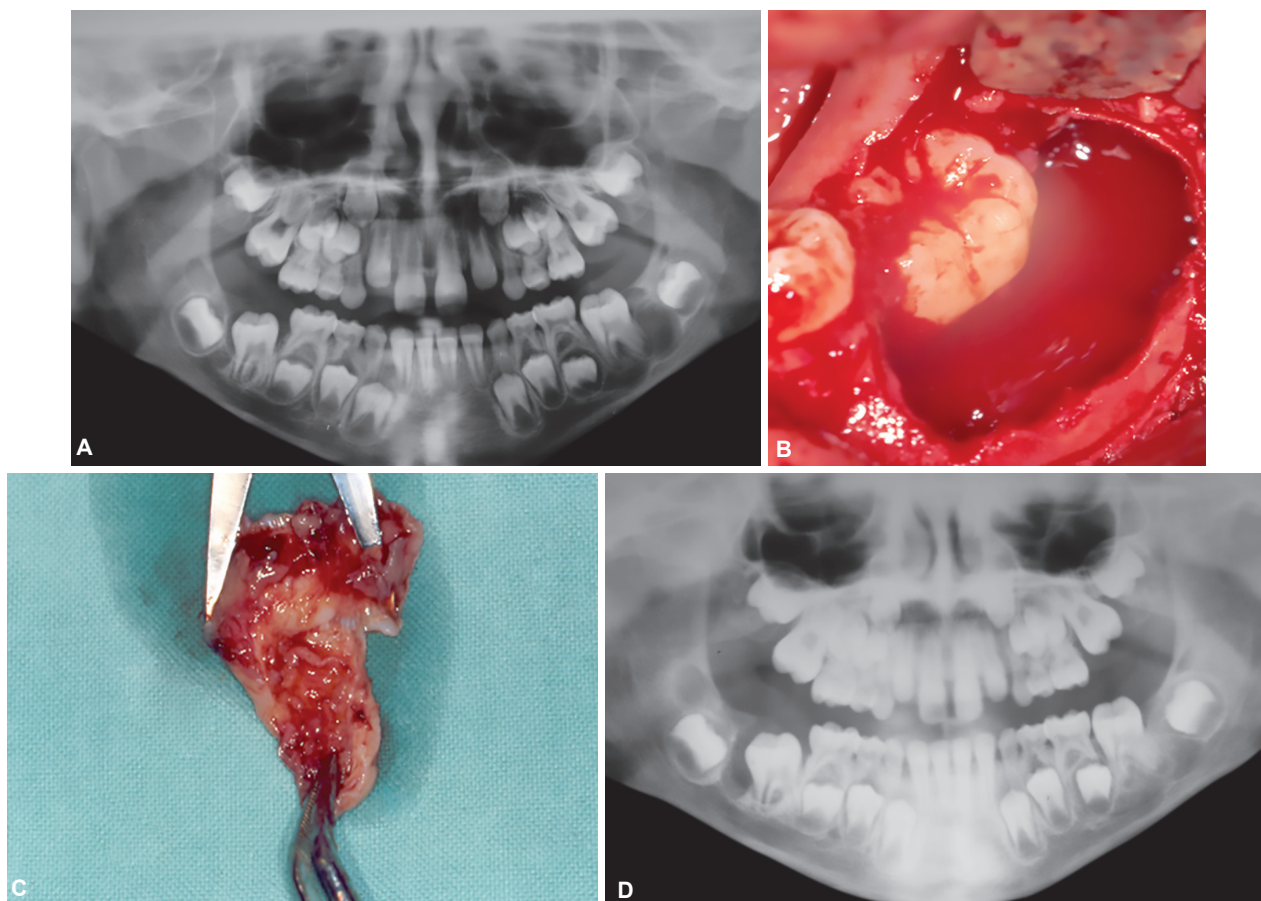
The clinical and radiological analysis allowed us to make a diagnosis of the dentigerous cyst, nevertheless histological examination is necessary to make a differential diagnosis whit other pathologies such as a large periapical cyst, odontogenic keratocyst or ameloblastic fibroma.

We decided to carry out an enucleation of the cyst located in 36 positions.

Clinical image document the size of the lesion (Figs 1B and C). The intervention was performed under regional anesthesia with mepivacaica 20 mg/mL and adrenalina 1:100.000. It was performing an incision in the middle of the edentulous ridge in 36 regions below the attached-gingiva, and it was elevated a full thickness flap to expose the underlying lesion. Then, the cystic linings were removed and curettage was done. The flaps were

approximated and sutured by a non-absorbable silk 4.0 suture with stapled point technique. After six months, the OPT showed the complete healing of the lesion and the correct eruption of 36 (Fig. 1D). After two years from the first surgical step, the lesion in 46 positions increased in dimensions, evaluated with OPT (Fig. 2), and it required a second surgery step to remove the cyst in the third quadrant, surgery was performed in the same way as the first one. Through the radiological follow-up at 18 months, we verified a favorable bone formation and the absence of recurrence.

After 6 years, the patient who reached the age of 17 does not have 47 elements in the arcade. Instead the contralateral spontaneously erupted. Diagnostic study with orthopantomographic (Fig. 3A) shown the presence of a third follicular cystic lesion in 47 positions which did not allow the correct eruptive process. It was necessary to program a third surgical step to remove the dentigerous cyst of 47, to allow the proper arcuate eruption. Simultaneously with cystic enucleation, the germectomy of 48 was performed. After twelve months, OPT showed a bone regeneration of surgical site and the correct eruption of 47 (Fig. 3B), but the pulp went in aseptic necrosis caused by the recision of a vascular nervous bundle of the same



Figs 1A to D: (A) Orthopantomographic reveals the presence of two radiolucent area that was present on right side of mandible in relation to first molar 3.6 and a similar lesion was evident even on left side of mandible in relation to the element 4.6; (B) The flap was elevate. We can see the underlying lesion; (C) The enucleated cyst; (D) After six months, the OPT has showed the complete healing of the lesion and the correct eruption of 3.6

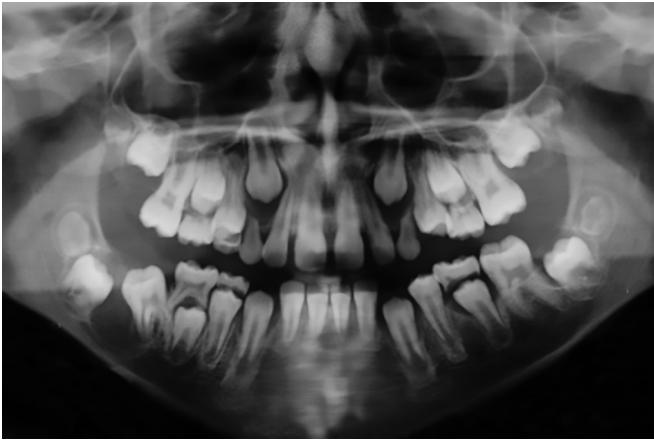


Fig. 2: Two years after the first surgery, a control OPT has performed in order to monitor the lesion in position 4.6

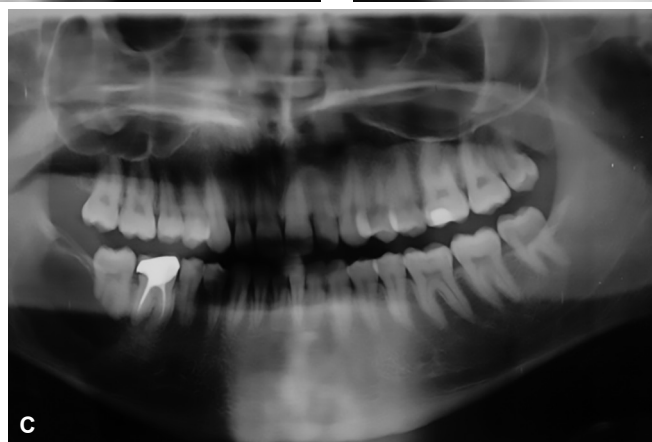
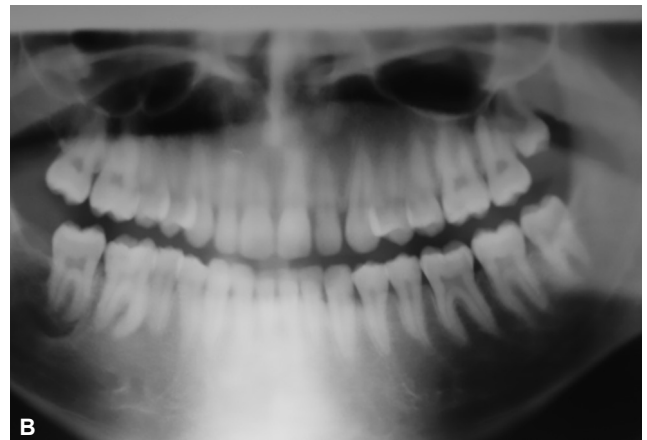
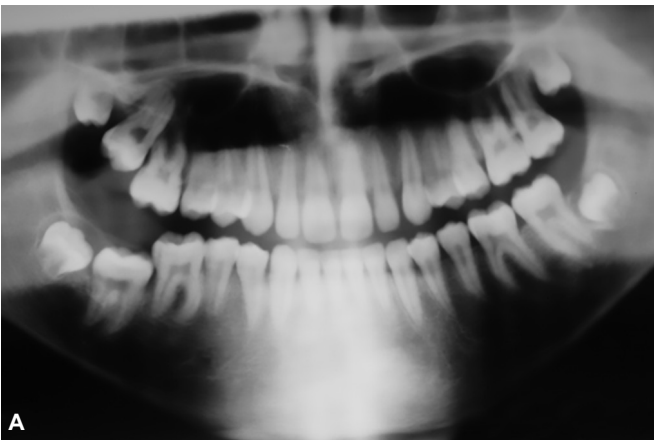
element. This event caused the development of an inflammatory radicular cyst, lead to the endodontic problem. After three years, this lesion increases his dimensions until it became clinical evident as a tumefaction of the third quadrant. The OPT (Fig. 3C) confirmed it showing a radiotransparent zone in 47 positions. It was, therefore, planned a marsupialization of the lesion and the contemporary extraction of the element 47 in the first surgical step, while in a second surgical step it was performed the enucleation of the cyst (Fig. 4A)

Loco-regional anesthesia was performed and a full-thickness flap was raised (Fig. 4B). The cyst was incised and the cystic walls were sutured to the surrounding gingiva to maintain access with the oral cavity and to foster a decompression of the cystic lesion. An elastic impression material was used to take the impression of the cavity aimed to create a removable partial denture that serves as an obturator with an arm which extended into the defect cavity (Fig. 4C). The treatment has lasted for 8 months (Fig. 4D).

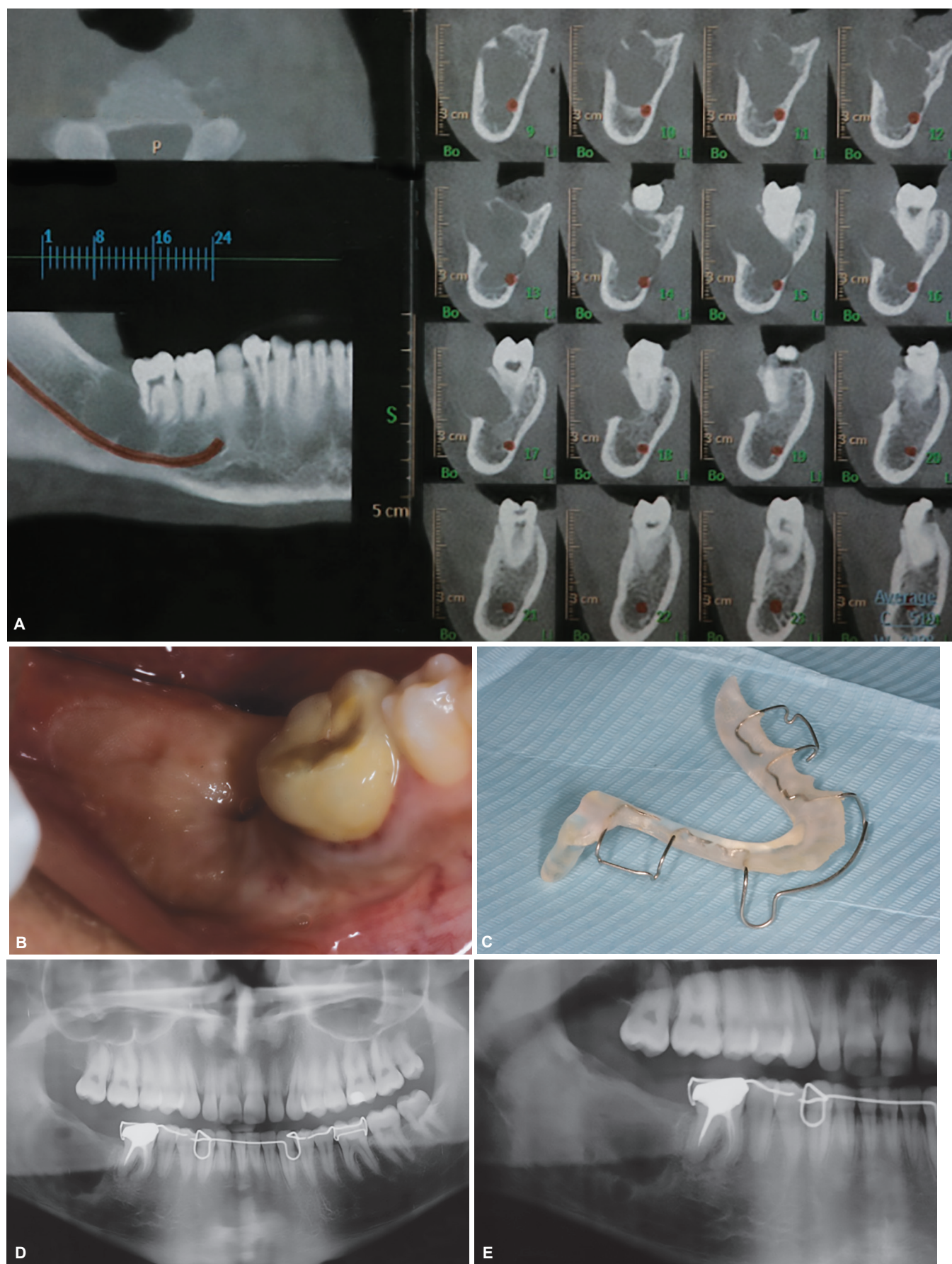
The postoperative treatment consists of analgesics and rinses with clorexidina 0.2% until the removal of the suture, which took place after 8 days. We decided to control weekly the patient for the first month and every two weeks for the rest of the treatment period. OPT showed a reduction of the size of the cavity and a consolidation of the bone surrounding the cyst (Fig. 4E).

It allowed us to proceed with a new surgical access to enucleate the cystic lesion.

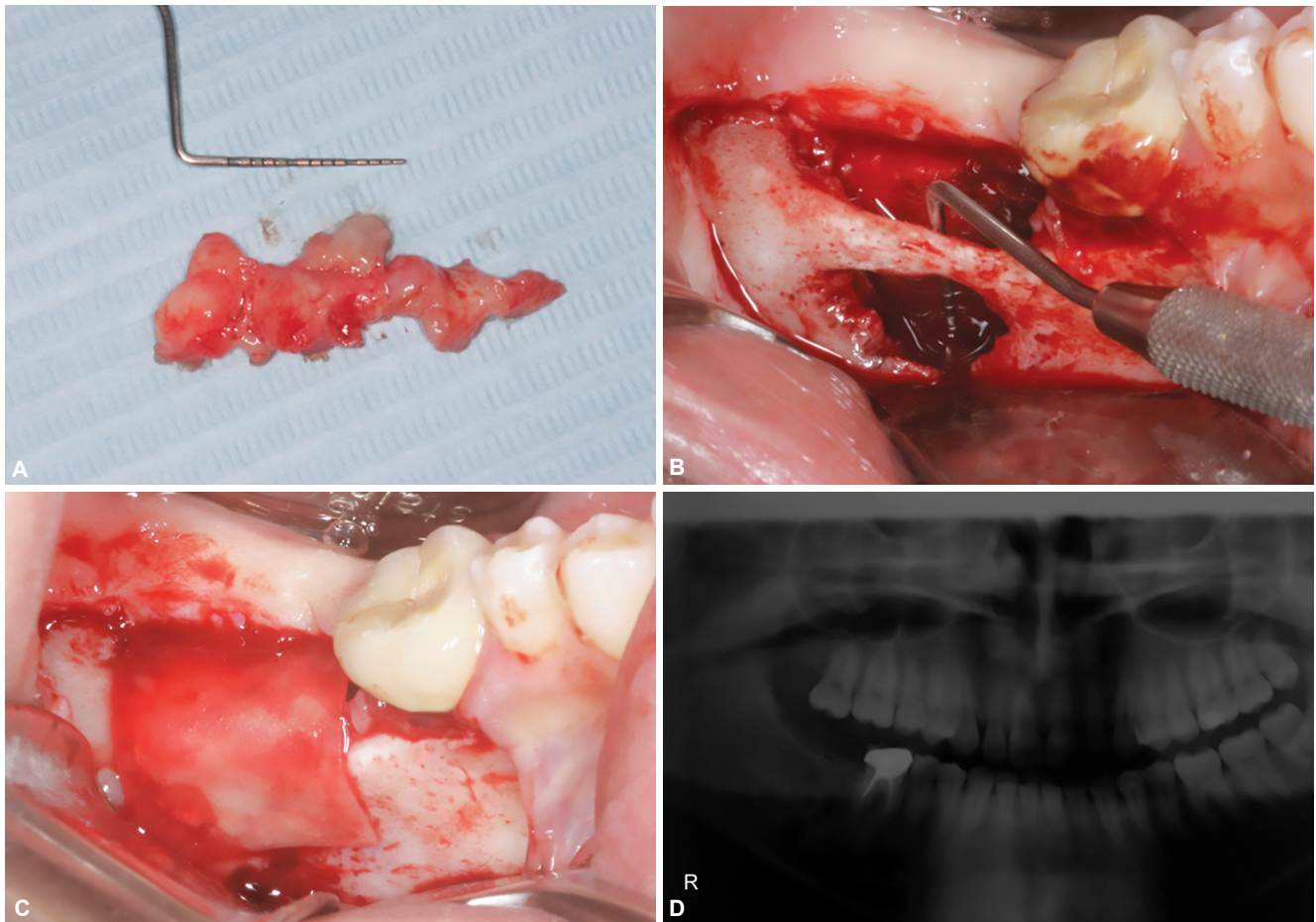
The surgery was performed under local anesthesia of the right mandible, allowing us to remove the cystic envelope (Fig. 5A). Also, due to the large crestal and vestibular cortical bone defect (Fig. 5B) and the poor retention derived, a collagen membrane was positioned before suturing the flaps (Fig. 5C) to stabilize the clot and to permit bone filling.



Figs 3A to C: (A) After six years orthopantomographic has shown the presence of a third follicular cystic lesion in 4,7; (B) The 12-month radiographic images has shown the almost total filling of the surgical site and the correct eruption of 4.7. it is also possible to note the presence of inflammatory cysts; (C) OPT has shown the presence of a radiolucent zone in 4.7 position



Figs 4A to E: (A) Cross-sections have allowed us to evaluate the anatomical relationship between the lesion and the lower alveolar nerve; (B) The marsupialization was performed with a crestal approach, in the 4.7 alveolar area; (C) After marsupialization a movable partial denture was used as an obturator with a sleeve which extended to the defect cavity; (D) OPT shows radicular cyst before marsupialization; (E) OPT shows radicular cyst after marsupialization



Figs 5A to D: Periodontal probe shows the size of the lesion; (B) The intraoperative image shows a wide crestal and vestibular bone defect; (C) A collagen membrane was positioned before suturing the flaps in order to stabilize the clot and let bone filling; (D) After 6 months, OPT has shown healing of inflammatory cyst

After the excisional treatment of the three mandibular bilateral dentigerous cysts the remission was complete (Fig. 5D), with no complications and recurrences after fourteen years of follow up. The correct eruptive process of the elements occurred without the aid of any orthodontic treatment. Pathological analysis of lesions of 36, 46 and 47 showed a cyst wall composed of fibrous tissue and lined by non-keratinized stratified squamous epithelium, and these findings confirmed the diagnosis of dentigerous cysts.

The conservative approach, to decompress the radicular inflammatory cyst through marsupialization in region 47, permitted to enucleate a cyst of smaller size than the initial one. Also, the healing of the inflammatory cyst was complete and with no signs of recurrences at six months. The histopathological analysis of this lesions showed a non-keratinized stratified squamous epithelium coat and a capsule of inflamed fibrous tissue. This result confirmed our diagnosis of radicular cyst.

DISCUSSION

The presence of multiple maxillary cysts is not associated with syndromic disease such as mucopolysaccharidosis,

basal cell nevus syndrome or Moroteaux–Laury syndrome is an extremely rare condition.^{4,5,19} Dentigerous cysts represent 25% of all cysts of the maxilla, second in order of frequency immediately after the radicular cysts.²⁸ They are localized in the mandible in 75%¹ of cases and the most involved dental elements are the lower third molar and the superior canine. In our knowledge since 1943 in literature 22 articles have been published which describes the presence of bilateral dentigerous cyst not associated with systemic disease.^{2,6-26} Eleven of these articles involve third inferior molar, six the first inferior molar, two the third maxillary molar, one the maxillary canine, the first maxillary molar, and the second inferior premolar. In the present case, our patient does not present any systemic pathological condition, and his medical history was negative. We found three cysts: one associated with a right mandibular first molar, one with left mandibular first molar and one with the right mandibular second molar; also, there was an inflammatory cyst that involves the right mandibular second molar. Thus, in the present case, the two dental inferior quadrants were involved with three cysts. As regards to the sex and the age of the patients, the reported cases involved 14 males and

7 females and are mainly involved patients under 15 years old in a range from 3 to 57 years. Our patients do not differ from data, in fact, he was 14 years old when we started the treatment. The greater frequency of cysts observed at this age is not accidental but caused by the eruption timing that occurs during this period of growth. As we just discuss these cysts, in general, are not symptomatic and a non-erupted tooth may be a sign of the presence of a dentigerous cyst. The frequency of the cyst is 1.44 per 100 non-erupted teeth.³ In the present case in addition to asymptomatic swelling, the patient also presented unerupted left and right mandibular first molar. In all reported cases, including the present case, radiographic examination showed a unilocular radiolucent lesion and well-defined sclerotic margins.

Consequently, the execution of an ohia proficiency test (OPT) is of fundamental importance if the patient has a non-erupted tooth to identify the presence of the cyst. If a lesion is present, the execution of an X-ray or technical component (TC) is essential to permit a more suitable delineation of the dimension of the cyst and its connection to surrounding anatomical structures. From a radiological point of view is important to value the size of the follicle. The normal size is about 3 cm if we exceed 5 cm we have to evaluate the presence of a cyst.²⁹ There are two possible treatments for cystic lesions, enucleation, and marsupialization. In all cases reported in the literature, enucleation was the treatment of choice. In the reported cases, in fact, 21 carried out an enucleation, only one enucleation associated with a marsupialization and in one case the authors decided not to carry out any treatment. Both of surgical approach has been used in this clinical case: enucleation was used in the treatment of three dentigerous cysts, and marsupialization for the treatment of radicular cyst. The decision on the type of treatment is taken in relation to the size of the cyst and the histological characteristics. If the cyst is capsulated and it can be easily detached from the surrounding bone, enucleation is generally performed.³⁰ The cystic cavity is filled whit blood and the clot will lead to new bone formation.

Furthermore, the enucleation permits to reduce patient morbidity and to decrease patient complications in the postoperative period such as infections, mandible fracture or the recurrence of the cyst. Finally, enucleation is performed in a single surgical time, so it is the quickest therapeutic approach.³⁰⁻³⁴ The aim of marsupialization is to reduce the inside pressure in order to reduce lesion,³²⁻³⁴ stimulating bone filling^{33,34} and increasing the thickening of the epithelial envelope with the aim to facilitate its subsequent enucleation.³¹ Moreover, marsupialization allows minimizing intraoperative complications.³¹⁻³⁴ A disadvantage of marsupialization is that it needs a good patient's compliance, also it is a longer treatment than enucleation.

Therefore, the indication for marsupialization is in large cysts and in compliant patients. In a study published by Enislidis et al.,³⁰ the decompression treatment of large mandibular cyst is evaluated. Twenty-four patients with different types of mandibular cysts with a diameter >40 mm were treated with marsupialization. The results show a reduction of the cyst's dimension of 80%, a low rate of complications and a treatment that makes the subsequent enucleation safer.

Nowadays, marsupialization is probably not the first choice for the treatment of mandibular cysts. Enucleation, in fact, is often the first therapeutic option, it does not require patient compliance and allows a reduction in treatment time.

Nevertheless, some conditions oblige us to perform a decompressive treatment. For example, the erosion of the roof of mandibular canal, or direct contact between the myelin sheath of the inferior alveolar nerve and the cyst, or the presence of little residual bone and the consequent risk of fracture of the jaw.

Another aspect to consider is the evaluation of the type of patient; understand if we are treating a compliant patient is a fundamental condition for the choice of treatment. We recommend the use of a marsupialization when the cyst is large and especially if it affects important anatomical structures making the treatment riskier. After a period of decompression can then be carried out an enucleation.

CONCLUSION

In the case of multiple dentigerous cysts, a deepen clinical and systematic examination should be done to rule out any associated syndrome.

Dentigerous cysts are usually asymptomatic with no pain or discomfort for the patient unless it becomes secondarily infected, they are frequently discovered in radiographs taken to investigate a failure tooth eruption or general dental examination so their evaluation can be difficult. Early diagnosis and treatment of the cyst are important because they allow us to avoid more aggressive surgical procedures and to reduce the mobility of the patients.

Nowadays in literature, there is not a single and significant orientation based on the results obtained from the various techniques, but this case report shows that through preoperative analysis of the lesion, the appropriate surgical strategy and its correct execution it is possible to achieve the expected therapeutic success even if in the same patient.

CLINICAL SIGNIFICANCE

From a clinical point of view, the case that we have described allows us to ascertain how a correct study of the

lesions in relation to its size, position, and characteristics allows us to have a more accurate, safe, predictable and durable therapeutic approach.

REFERENCES

- Weber AL. Imaging of the cysts and odontogenic tumors of the jaw. Definition and classification. *Radiol Clin North Am*. 1993 Jan;31(1):101-120.
- O'Neil DW, Mosby EL, Lowe JW. Bilateral mandibular dentigerous cysts in a five-year-old child: report of case. *ASDC J Dent Child* 1989 Sep-Oct;56:382-384.
- Shafer H, Levy. Cyst and tumors of odontogenic origin in Shafers textbook of oral pathology; pp. 358-361. 5th ed. New Delhi: Elsevier India; 2007.
- Roberts MW, Barton NW, Constantopoulos G, Butler DP, Donahue AH. Occurrence of multiple dentigerous cysts in a patient with the Maroteaux-Lamy syndrome (mucopolysaccharidosis, type VI). *Oral surgery, oral medicine, oral pathology*. 1984 Aug 1;58(2):169-75.
- Johnson NR, Gannon OM, Savage NW, Batstone MD. Frequency of odontogenic cysts and tumors: a systematic review. *Journal of investigative and clinical dentistry*. 2014 Feb;5(1):9-14.
- Myers PB. Bilateral dentigerous cysts of the mandible. *Br Dent J* 1943;74:67-68.
- Henefer EP. Bilateral dentigerous cysts of the maxilla. Report of a case. *Oral Surg Oral Med Oral Pathol* 1964 Mar;17:296-298.
- Stanback JS. The management of bilateral cysts of the mandible. *Oral Surg Oral Med Oral Pathol* 1970 Nov;30:587-591.
- Callaghan JH. Bilateral impaction of lower third molars in association with bilateral dentigerous cyst formation. A case report. *Glasg Dent J* 1973 Spring;4:36-38.
- Burton DJ, Scheffer RB. Serratia infection in a patient with bilateral subcondylar impacted third molars and associated dentigerous cysts: report of case. *J Oral Surg* 1980 Feb;38:135-138.
- Swerdlhoff M, Alexander SA, Ceen RF, Ferguson FS. Bilateral mandibular dentigerous cysts in a seven-year-old child. *J Pedod* 1980 Fall;5:77-84.
- Crinzi RA. Bilateral dentigerous cysts of the mandible. *Oral Surg Oral Med Oral Pathol* 1982 Sep;54:367.
- McDonnell DG. Bilateral dentigerous cysts. A case history. *J Ir Dent Assoc* 1988 Jan;34:63.
- Eidinger GB. Bilateral dentigerous cysts in the child patient. Report of a case and review of the literature. *Univ Tor Dent J* 1989 Spring;2:20-23.
- Banderas JA, Gonzalez M, Ramirez F, Arroyo A. Bilateral mucous cell containing dentigerous cysts of mandibular third molars: report of an unusual case. *Arch Med Res* 1996 Autumn;27:327-329.
- Sands T, Tocchio C. Multiple dentigerous cysts in a child. *Oral Health* 1998 May;88:27-29.
- De Biase A, Ottolenghi L, Polimeni A, Benvenuto A, Lubrano R, Magliocca FM. Bilateral mandibular cysts associated with cyclosporine use: a case report. *Pediatr Nephrol* 2001 Dec;16:993-995.
- Batra P, Roychoudhury A, Balakrishnan P, Parkash H. Bilateral dentigerous cyst associated with polymorphism in chromosome 1qh p. *J Clin Pediatr Dent* 2004 Winter;28:177-181.
- Ko KS, Dover DG, Jordan RC. Bilateral dentigerous cysts – Report of an unusual case and review of the literature. *J Can Dent Assoc* 1999 Jan;65:49-51.
- Shah N, Thuau H, Beale I. Spontaneous regression of bilateral dentigerous cysts associated with impacted mandibular third molars. *Br Dent J*. 2002 Jan;192:75-76.
- Yamalik K, Bozkaya S, Erkmen E, Baris E. Nonsyndromic bilateral mandibular dentigerous cysts: Report of a rare case. *Turkiye Klinikleri J Dent Sci*. 2007;13:129-134.
- Imada TS, Neto VT, Bernini GF, Silva Santos PS, Rubira-Bullen IR, Bravo-Calderón D. Unusual bilateral dentigerous cysts in a nonsyndromic patient assessed by cone beam computed tomography. *Contemp Clin Dent*. 2014 Apr;5(2):240-242.
- Fregnani ER, Perez DE, de Carvalho PA, Alves FA. Metachronous bilateral dentigerous cysts associated with permanent first molars. *J Dent Child (Chic)* 2008 May-Aug;75:197-200.
- Sergio EV, Maria DP, Sergio EN. Bilateral dentigerous cyst in a non syndromic patient: Case report and literature review. *Am Acad Pediatr Dent*. 2009 Jan;76:92-96.
- Ustuner E, Fitoz S, Atasoy C, Erden I, Akyar S. Bilateral maxillary dentigerous cysts: a case report. *Oral Surgery, Oral Medicine, Oral Pathology, Oral Radiology, and Endodontology*. 2003 May 1;95(5):632-635.
- Freitas DQ, Tempest LM, Sicoli E, Lopes-Neto FC. Bilateral dentigerous cyst: Review of literature and report of unusual case. *Dento Maxillofac Radiol*. 2006 Nov;35:64-68.
- Norris L, Piccoli P, Papageorge MB. Multiple dentigerous cysts of the maxilla and the mandible: report of a case. *J Oral Maxillofac Surg* 1987 Aug;45:694-697.
- Daley TD, Pringle GA. Relative incidence of odontogenic tumors and oral and jaw cysts in a Canadian population. *Oral Sur Oral Med Oral Pathol* 1994 Mar;77:276-80.
- Neville BW, Damm DD, Allen CM, Bonquot JE. 2nd ed. Philadelphia. P.A: W.B. Saunders; 2005. Odontogenic cysts and tumors. *Oral and Maxillofacial pathology*; pp. 591-592.
- Enislidis G, Focka N, Sulzbacher I, Ewers R. Conservative treatment of large cystic lesions of the mandible: a prospective study of the effect of decompression. *Br J Oral Maxillofac Surg* 2004 Aug;42:546-550.
- Sakkas N, Schoen R, Schulze D, Otten JE, Schmelzeisen R. Obturator after marsupialization of a recurrence of a radicular cyst of the mandible. *Oral Surgery, Oral Medicine, Oral Pathology, Oral Radiology, and Endodontology*. 2007 Jan 1; 103(1):e16-18.
- Delilbasi C, Yuzbasioglu E, Aydin K. Complete healing of radicular cysts only by marsupialization. *J Clin Case Rep* 2:199.
- Riachi F and Tabarani C. Effective Management of Large Radicular Cysts Using Surgical Enucleation vs. Marsupialization Two Cases Report. *Int Arab J Dent* 2010 Jan;(1)1.
- Delbem ACB, Cunha RF, Vieira AEM, Pugliesi DMC. Conservative treatment of a radicular cyst in a 5-year-old child: a case report. *Int J Paediatr Dent* 2003 Nov;13:447-450.