

A Tailored Approach for Growth Modification: An Innovative Approach

¹Narendra Sharma, ²Sunita Shrivastav, ³Ranjit Kamble, ⁴Preethi Sharma

ABSTRACT

Aim: The aim of this study is to evaluate the treatment effects of the clear block appliance during comprehensive correction of class II malocclusion in growing patients.

Introduction: Sagittal discrepancy commonly exists in skeletal class II malocclusions. The popular of the class II malocclusions is division 1 type among them. The presence of original skeletal jaw abnormality is the origin of the class II malocclusions. The treatment result of such skeletal malocclusion depends on the age, latent growth, and cooperation of the individual. The class II division 1 malocclusion in a growing individual can be successfully treated with different types of myofunctional appliance. The present article illustrates a new approach (clear block appliance) to correct sagittal discrepancy to make optimal use of the patient's pubertal growth spurt to achieve best possible results. Based on the results in these patients, the clear block appliance was very effective in correcting class II malocclusions. Although the results are positive, they should be tested on a large sample size.

Clinical significance: Clear block appliance proved to be the best alternative to other myofunctional appliances, where side effects in the form of anchorage loss or proclination of lower incisor do not occur with similar results.

Keywords: Clear block appliance, Dentofacial orthopedics, Growing skeletal class II malocclusion, Orthodontics.

How to cite this article: Sharma N, Shrivastav S, Kamble R, Sharma P. A Tailored Approach for Growth Modification: An Innovative Approach. World J Dent 2017;8(4):334-342.

Source of support: Nil

Conflict of interest: None

INTRODUCTION

Among the different forms of class II malocclusion, class II division 1 is frequently seen. As indicated by McNamara, in children of class II division 1 malocclusion with latent growth, the most frequent element is increase in overjet and retroposition of mandible. It is most of the time made complex by the presence of original skeletal jaw inconsistency, due to forwardly placed maxilla,

retroposition mandible, or a combined effect of both. The treatment result of such skeletal malocclusion depends on the age, latent growth, and cooperation of patient.¹

To treat the skeletal jaw discrepancy, measures undertaken for favorable growth changes can be carried out during the late mixed or early permanent dentition before the completion of latent growth. In individuals whose growth spurts are toward the end or who are uncooperative, fixed functional appliance can be used such as Jasper jumper, Herbst appliance or forsus fatigue resistance devices. In the patients with less discrepancy and toward the end of growth potential, it is impossible to carry out growth modification procedures. Such cases, with the discrepancy in skeletal jaw bases, can be addressed by orthodontics with or without extractions and orthognathic surgery.

In the individuals with no growth potential where the jaw discrepancy is more, the combined orthodontic and orthognathic surgeries can provide best treatment results.²⁻⁵

Appliance

Skeletal class II cases where mandible is retrognathic and with increased overjet are selected for clear block therapy.

This appliance has no wire components with possibility of reduction in overjet with no undesired incisor proclination.

Timing of Treatment

The best time to deliver clear block appliance to correct class II malocclusion is during pubertal growth spurt to utilize maximum treatment effect and trim down the time required for retention.

Appliance Fabrication

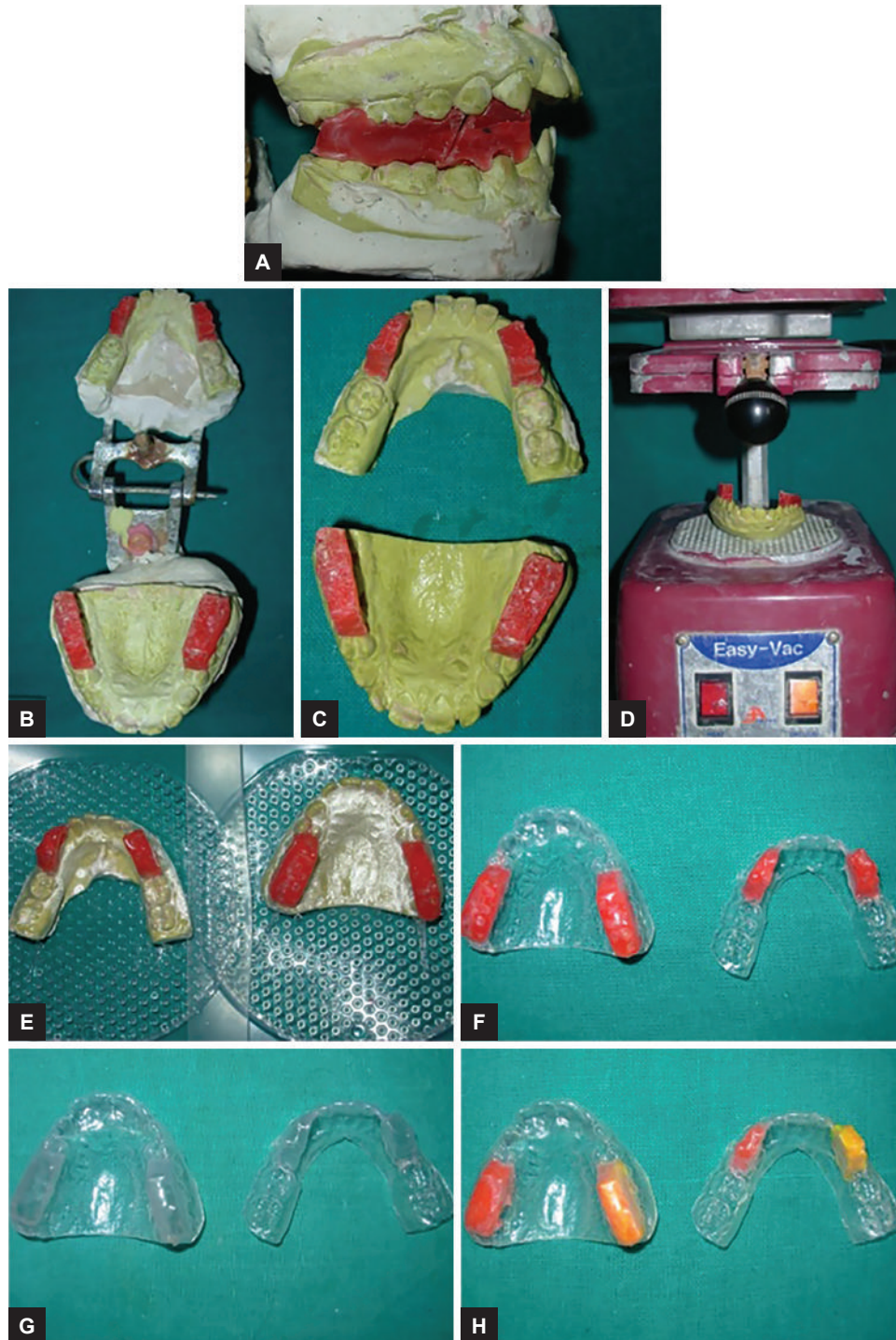The appliance is fabricated as described (Figs 1A–H):

- Impressions and working model preparation.
- Bite registration is taken with advancement of mandible so that the molars are in class I relation and interincisal opening should not be more than 2 mm.
- Make a cut in a wax bite with angle of 45 to 60° (Fig. 1).
- Place a clear thermoplastic sheet over vacuum press along with wax bite block on cast (Fig. 1D).

¹⁻³Department of Orthodontics, Sharad Pawar Dental College & Hospital, Wardha, Maharashtra, India

⁴Department of Oral Pathology, Sharad Pawar Dental College & Hospital, Wardha, Maharashtra, India

Corresponding Author: Narendra Sharma, Department of Orthodontics, Sharad Pawar Dental College & Hospital, Wardha Maharashtra, India, e-mail: sharmannarendra047@gmail.com



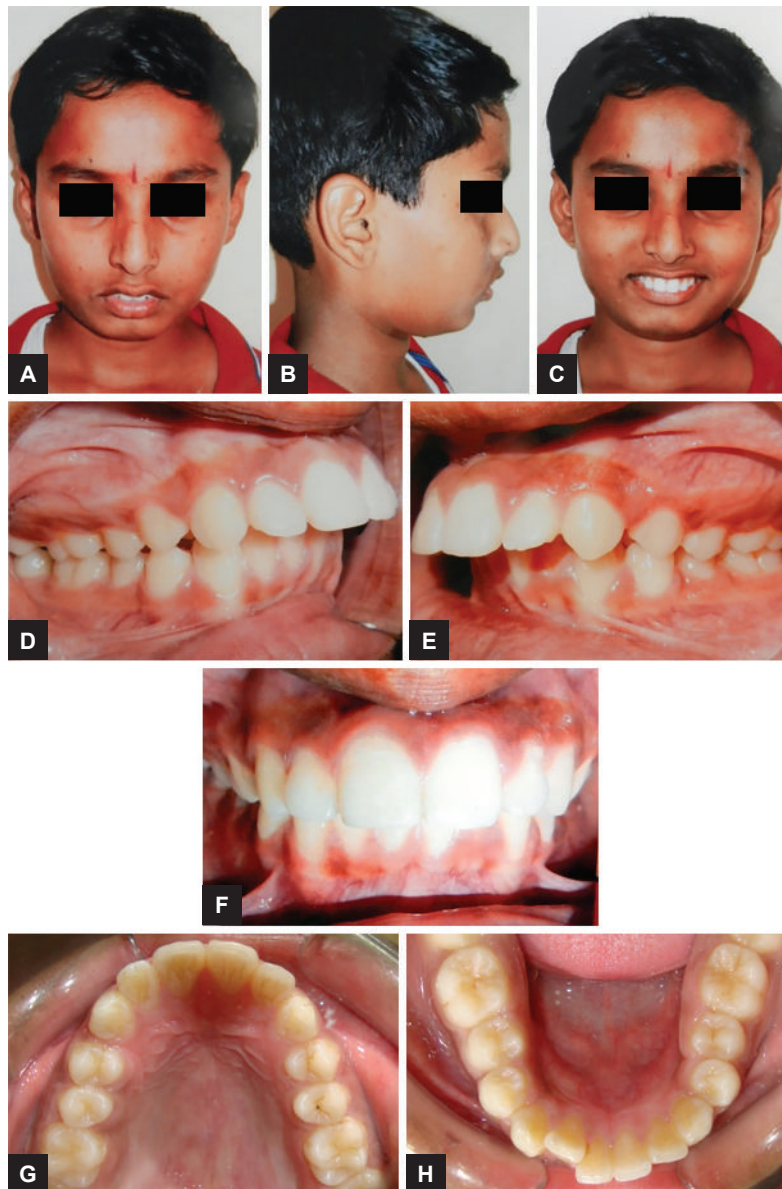
Figs 1A to H: Steps in fabrication of clear block appliance

- *Dewaxing:* After trimming excess sheet, keep them in hot water to remove wax from the plates and remnant of wax from working models.
- *Acrylization:* Fill the self-curing acrylic resin of the proper consistency in the wax block space. Keep the plate back on the cast. After setting of acrylic resin, remove the plates and trim the edges of clear block appliance (Fig. 1H).
- *Trying of clear block appliance:* Upper and lower plates are inserted in the mouth and the patient is asked to close the mandible in a forward position.

CASE REPORTS

Case 1

A male aged 13 years with labially placed upper anterior teeth and unpleasant esthetics had come to the Department of Orthodontics to seek treatment. Extraoral examination showed convex profile with retrognathic mandible. Intraoral examination showed late permanent dentition stage with "U"-shaped dental arches and the maxillary anterior proclined. Molars were in class II relationship with overjet of 8 mm and deep bite of 5 mm in occlusion



Figs 2A to H: Pretreatment extraoral and intraoral photographs of case 1

(Fig. 2). The cephalogram showed A point, nasion, B point angle (ANB) angle of 7° . The sella-nasion-subspinale (SNA) angle measuring 80° showed that maxilla was normal with respect to the anterior cranial base. The SNB angle measuring 73° showed retrognathic mandible with respect to the anterior cranial base. The maxillary incisors were in labial version (Fig. 3).

Diagnosis

Class II skeletal and dental relation was with normal growth pattern of the mandible.

Treatment Plan

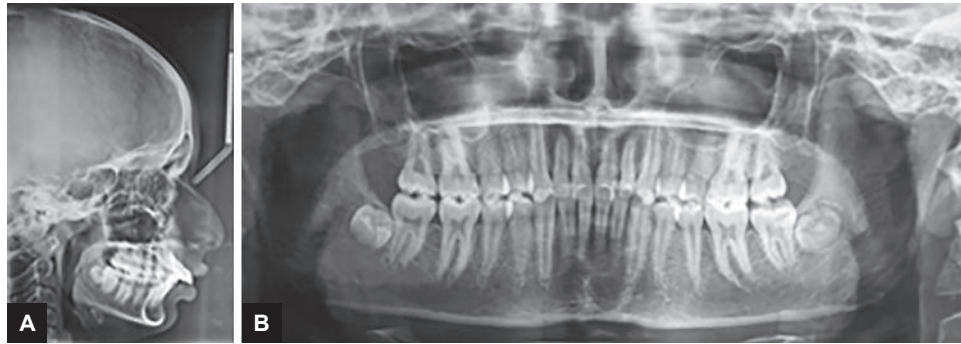Interception of class II skeletal relationship by growth modification procedure with clear block appliance therapy (Fig. 4), followed by fixed orthodontic appliance for finishing and detailing of occlusion.

RESULTS

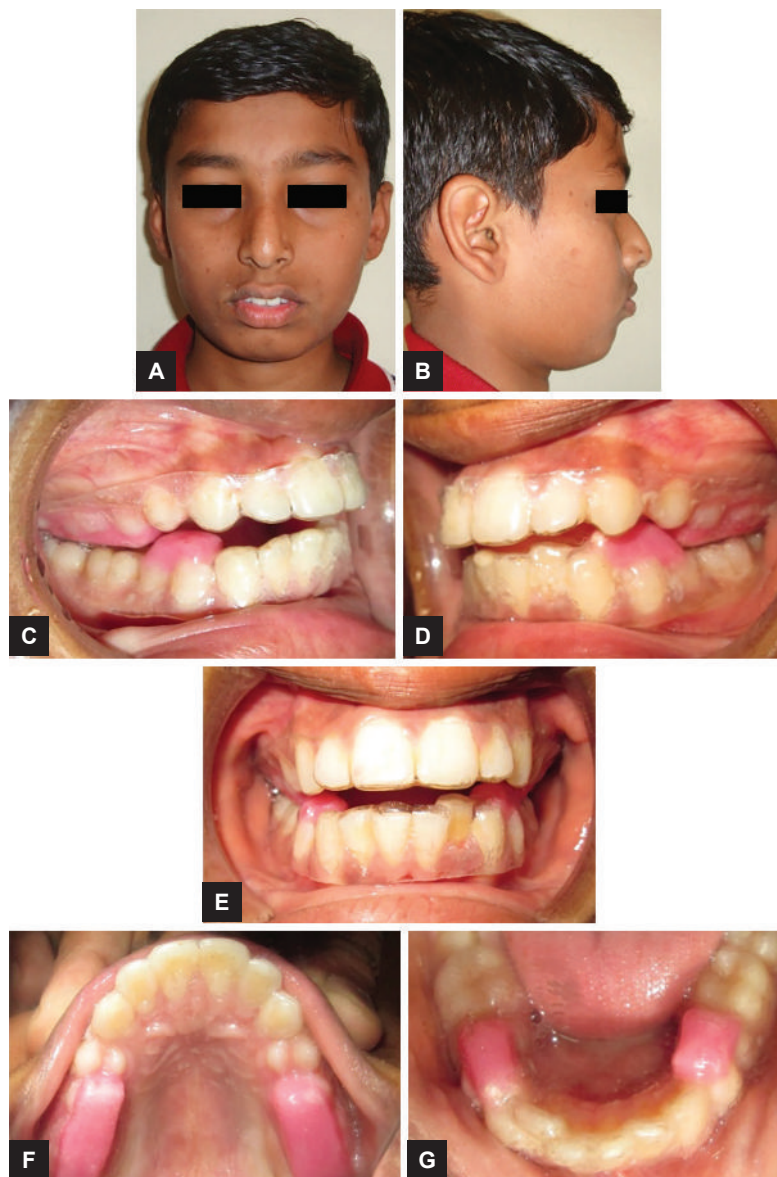
Clear block appliance significantly improved the class II skeletal and dental relationships with improvement in soft tissue facial contour, along with lip competency with decrease in the overjet and deep bite (Fig. 5). The cephalometric analysis (Fig. 6) after clear block appliance therapy showed favorable growth of the mandible. There was a decrease in the ANB angle. The posttreatment SNB measuring 78° indicates the favorable growth of mandible. Pre and postcorrection cephalometric values are shown in Table 1.

Case 2

A girl aged 12 years presented with chief complaint of forwardly placed upper anterior teeth with difficulty in closing lips. On extraoral examination, it was revealed that there was convex facial profile with protrusive,



Figs 3A and B: (A) Pretreatment cephalogram; and (B) orthopantomogram of case 1

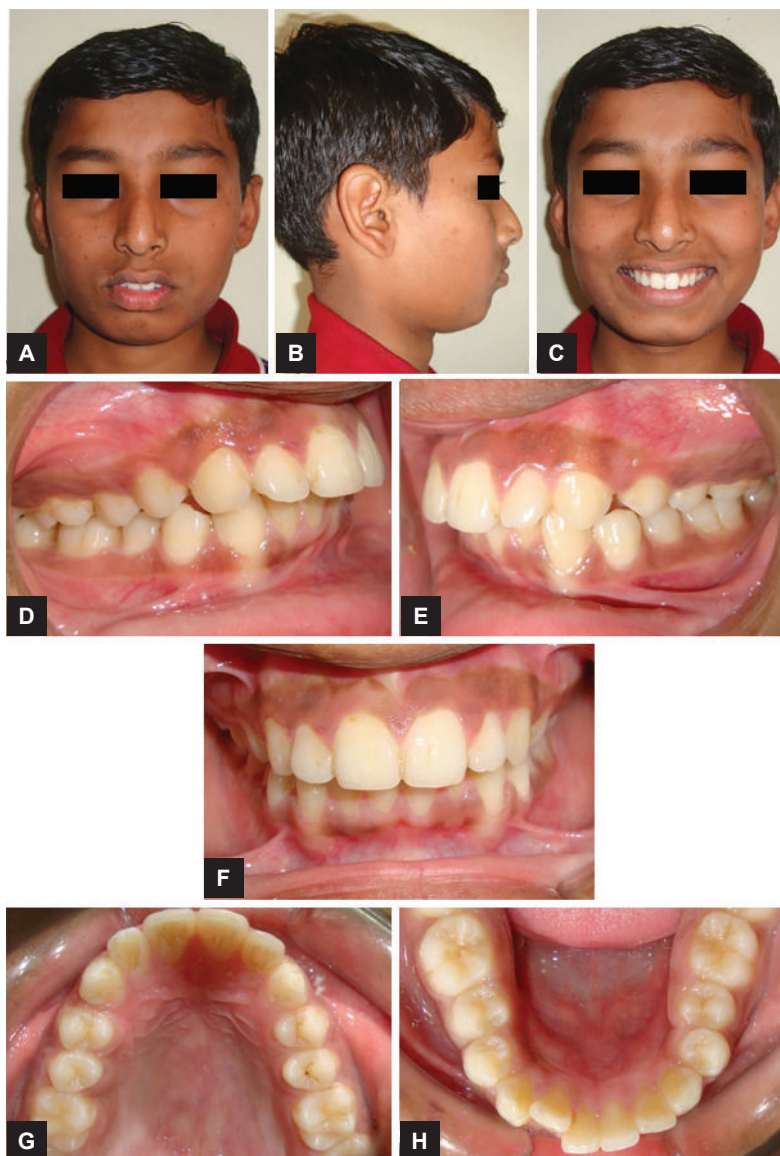


Figs 4A to G: Clear block appliance delivered in case 1

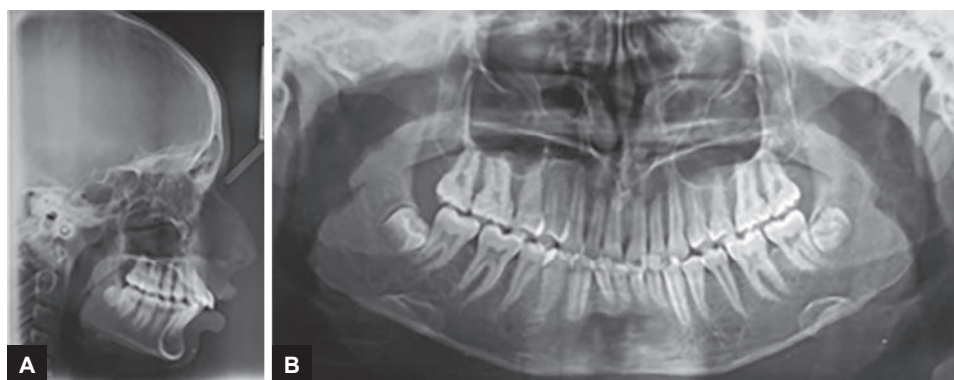hypotonic upper lip with 5 mm apart, everted lower lip, and retrognathic mandible.

Intraoral examination showed U-shaped arches with proclined upper anterior with mild spacing between them and increases in overjet of 9 mm and overbite of

8 mm. There were a canine and molar in class II relationship (Fig. 7). On tracing lateral cephalogram, the ANB angle measured 6° . The SNA angle measuring 81° showed that the maxilla was normal in relation to the anterior cranial base. The sella-nasion-B point angle (SNB) angle



Figs 5A to H: Posttreatment extraoral and intraoral photographs of case 1



Figs 6A and B: (A) Posttreatment cephalogram; and (B) orthopantomogram of case 1

measuring 75° showed that mandible was retrognathic in relation to the anterior cranial base. The value for growth pattern showed horizontal growth pattern (Fig. 8).

Diagnosis

Class II skeletal and dental relation with normal growth pattern of mandible.

Table 1: Pretreatment and postfunctional cephalometric values of case 1

| Parameter | Pretreatment value | Postfunctional |
|---------------------------|--------------------|----------------|
| SNA | 80° | 80° |
| SNB | 73° | 78° |
| ANB | 7° | 2° |
| Nasolabial angle | 96° | 102° |
| U1 to NA | 31° | 30° |
| L1 to NB | 28° | 28° |
| IMPA | 100° | 100° |
| Go-Gn to SN | 30° | 31° |
| Mandibular length (Co-Gn) | 102 mm | 104 mm |

IMPA: Incisor mandibular plane angle; Go-Gn: Gonion-Gnathion; NA: Nasion-point A; NB: Nasion-point B; SN: Sella-nasion

Treatment Plan

Growth modulation to treat underline skeletal jaw discrepancy with clear block appliance therapy (Fig. 9), followed by fixed orthodontic appliance for finishing and detailing of occlusion.

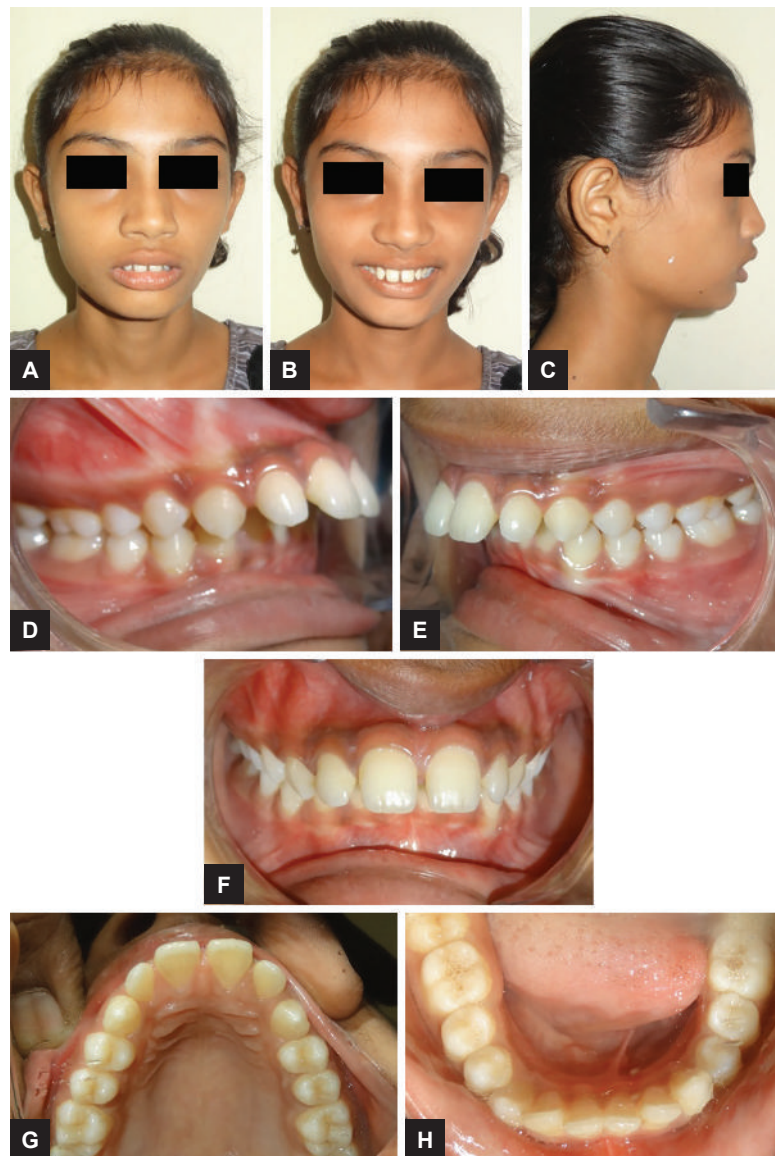
RESULTS

Skeletal and dental class I relationships were achieved with improvement in soft tissue facial outline, along with lip competency with reduction in the overjet and overbite (Fig. 10). On tracings (Fig. 11), it was found that there is reduction in the ANB angle of 3° with favorable growth of the mandible. The postcorrection SNB angle measures 78°. Pre and postcorrection cephalometric values are given in Table 2.

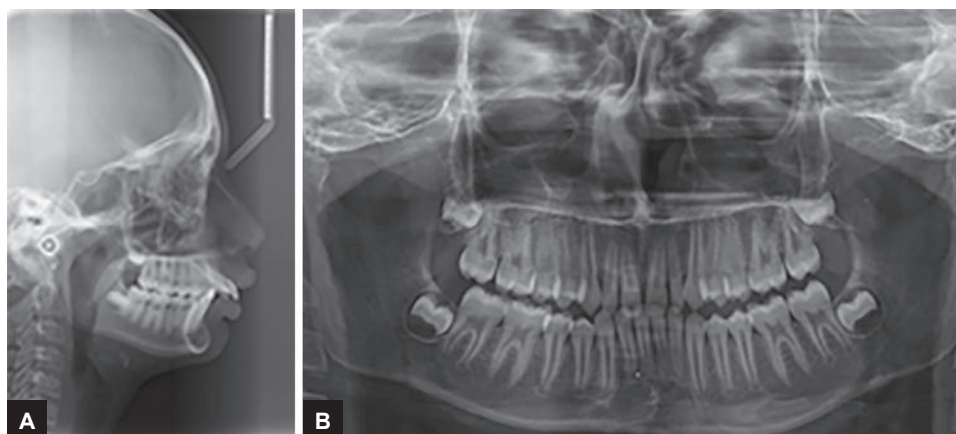
DISCUSSION

Class II malocclusion presents several numbers of combinations of skeletal and dental features. Hence, identifying the cause of class II malocclusion and forming the right approach are necessary for its correction.

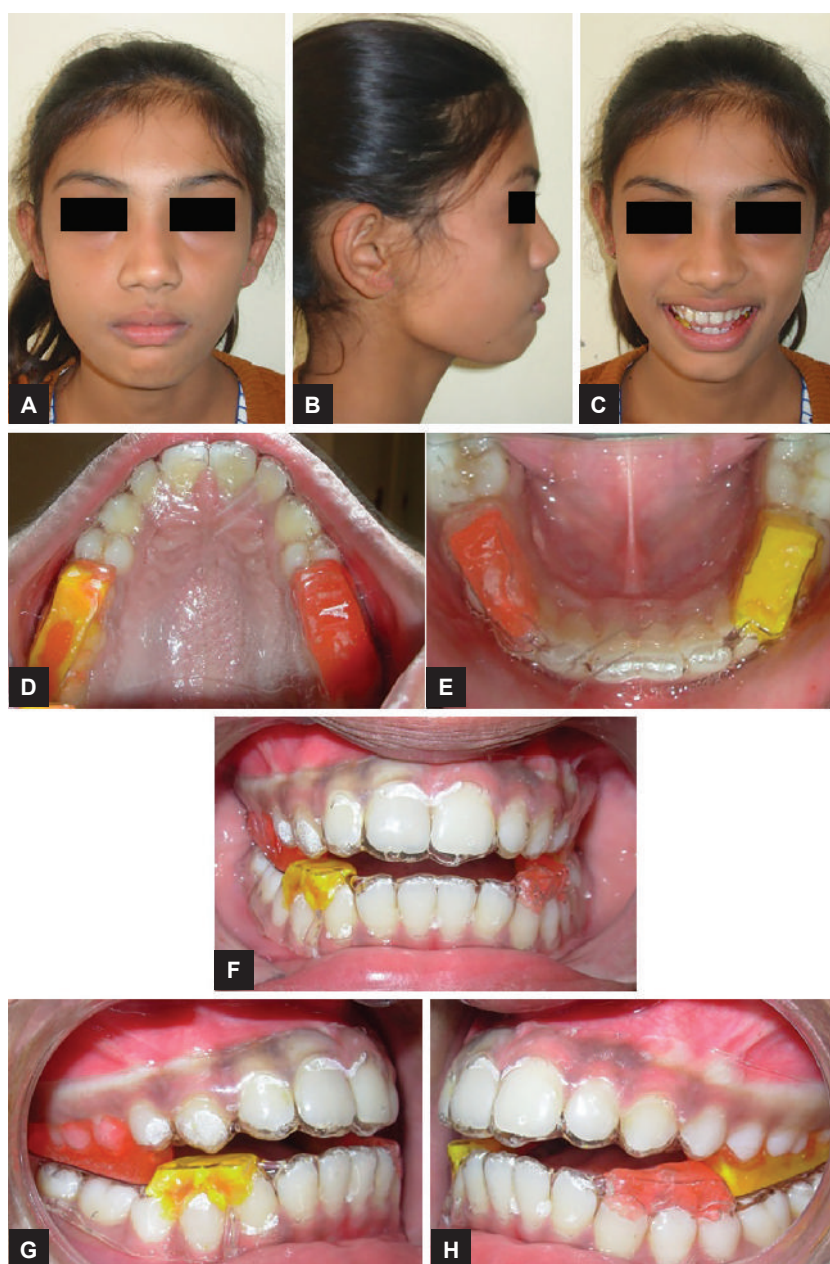
In general, it is believed that a skeletal class II malocclusion is frequently caused by maxilla positioned



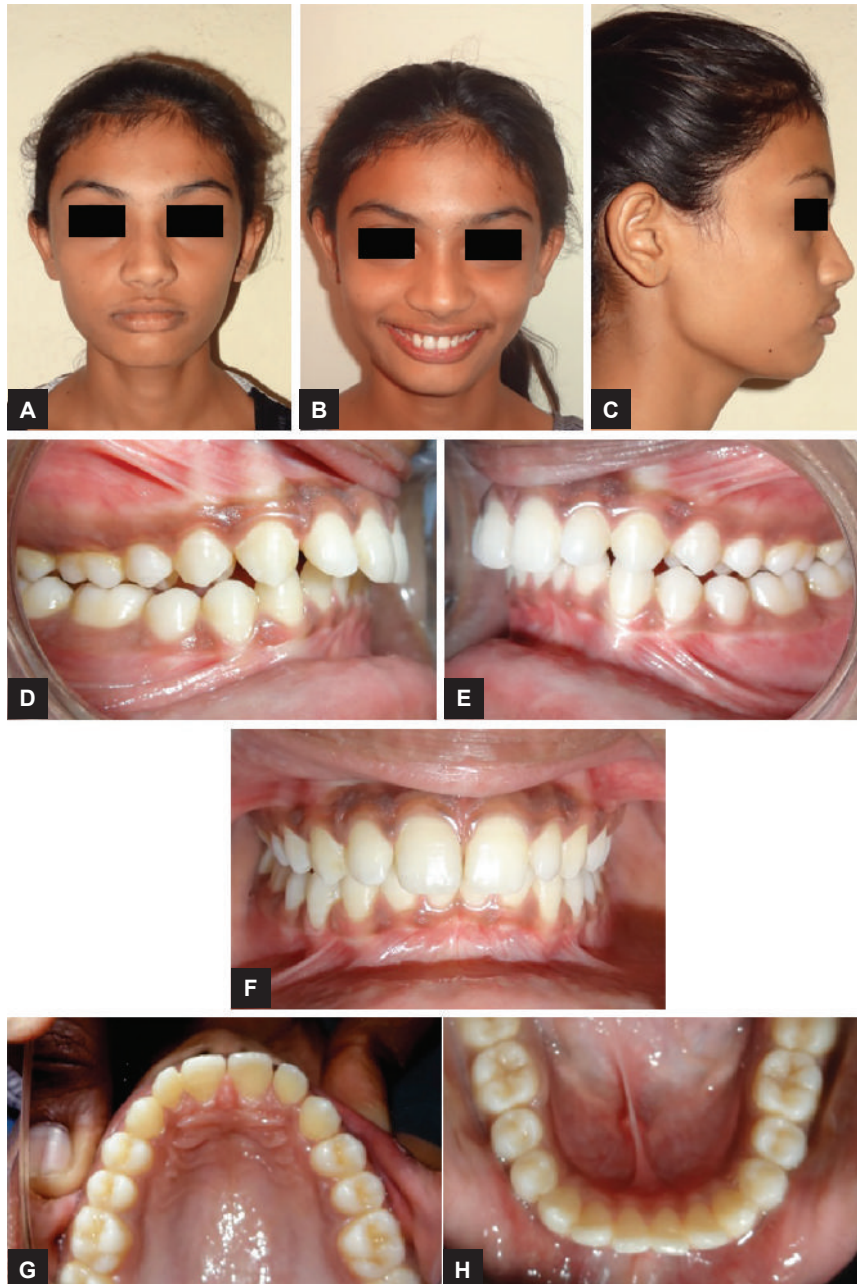
Figs 7A to H: Pretreatment extraoral and intraoral photographs of case 2



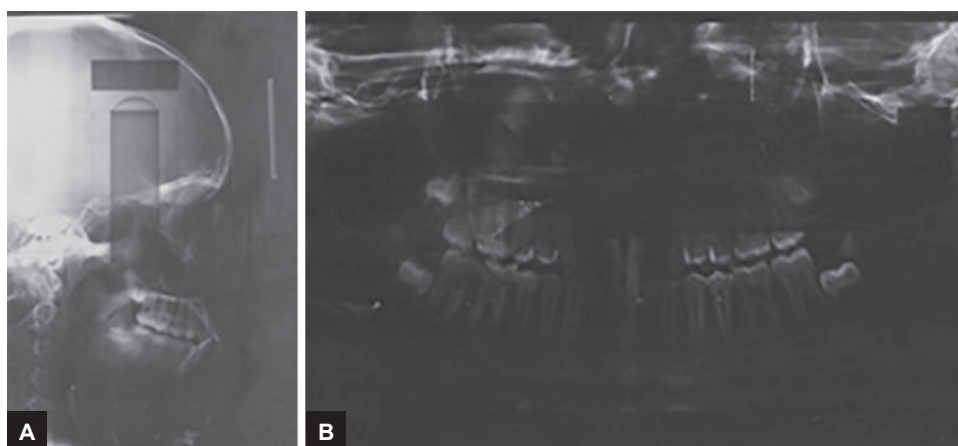
Figs 8A and B: (A) Pretreatment cephalogram; and (B) orthopantomogram of case 2



Figs 9A to H: Clear block appliance delivered in case 2



Figs 10A to H: Posttreatment extraoral and intraoral photographs of case 2



Figs 11A and B: (A) Posttreatment cephalogram; and (B) orthopantomogram of case 2

Table 2: Pretreatment and postfunctional cephalometric values of case 2

| Parameter | Pretreatment value | Postfunctional |
|---------------------------|--------------------|----------------|
| SNA | 81° | 81° |
| SNB | 75° | 78° |
| ANB | 6° | 3° |
| Nasolabial angle | 97° | 105° |
| U1 to NA | 35° | 34° |
| L1 to NB | 28° | 28° |
| IMPA | 99° | 99° |
| Go-Gn to SN | 27° | 28° |
| Mandibular length (Co-Gn) | 100 mm | 103 mm |

normal with a more retroposition mandible. During the active growth period, it is best to take advantage of myofunctional appliances to correct skeletal relationship and modify the position of the mandible, both antero-posteriorly and vertically, by the stimulating effect at the condylar cartilage. Correction of mandible retrusion can be done using a variety of myofunctional appliances. Every advocator of the different myofunctional appliances has considered more or less his own theory and working hypothesis: Andresen, Haupl, and Herren for the activator, Balters for the bionator, Rolf Frankel for the functional regulator, and Clark for the Twin Block.⁴⁻¹¹ Functional appliances work in two ways: Either force application or force elimination. The new pattern of function using myofunctional appliances develops a new morphological prototype. It corrects the underline imbalance in muscle, thus changing tone of soft tissue and oronasopharyngeal complex function. Orthopedic effect of myofunctional appliances mainly influences the facial skeleton of growing individual by inducing alteration in condylar and sutural areas. The mandibular effect is observed along with the maxillary effect. When the mandible is constantly held forward by the appliance, the stretch of the soft tissues exerts a reactionary force toward the maxilla and slight maxillary restraint suggesting a headgear effect, serving to correct class II tendency.¹²⁻¹⁴

The rationale of developing clear block appliance was to formulate a method that could modify the growth of jaws in desired direction and, i.e., simple, esthetic, and functional with least side effects on dentition. The clear block appliance modifies the growth of mandible with the following advantages.

Advantages

- Only tooth-borne myofunctional appliance with no wire component
- No proclination of lower incisors as all teeth are covered with clear thermoplastic material
- Full-time wear except when brushing

- Easy removal and insertion
- Fabrication is quick
- No need to articulate the cast on articulator
- Less breakage and adjustment than the other acrylic appliances and metallic fixed functional appliances.

CONCLUSION

In the growing individual, interception of skeletal class II malocclusion by alteration in growth direction is the best treatment option for mandibular retrognathism, which can be achieved by myofunctional appliances. Diagnosis and case selection are important. Clear block appliance proved to be the best alternative to other myofunctional appliances, where side effects in the form of anchorage loss or proclination of lower incisor do not occur with similar results.

REFERENCES

1. McNamara JA Jr. Components of Class II malocclusion in children 8-10 years of age. *Angle Orthod* 1981 Jul;51(1):177-202.
2. Hsieh TJ, Pinskaya Y, Roberts WE. Assessment of orthodontic treatment outcomes: early treatment versus late treatment. *Angle Orthod* 2005 Mar;75(2):162-170.
3. Tulloch JF, Phillips C, Proffit WR. Benefit of early Class II treatment: progress report of a two-phase randomized clinical trial. *Am J Orthod Dentofacial Orthop* 1998 Jan;113(1):62-72, quiz 73-74.
4. Dugoni SA. Comprehensive mixed dentition treatment. *Am J Orthod Dentofacial Orthop* 1998 Jan;113(1):75-84.
5. King GJ, Keeling SD, Hoyer RA, Wheeler TT. The timing of treatment for Class II malocclusion in children; a literature review. *Angle Orthod* 1989 Summer;60(2):87-97.
6. Bowman SJ. One-stage versus two-stage treatment: are two really necessary? *Am J Orthod Dentofacial Orthop* 1998 Jan;113(1):111-116.
7. White L. Early orthodontic intervention. *Am J Orthod Dentofacial Orthop* 1998 Jan;113(1):24-28.
8. Wieslander L, Lagerström L. The effect of activator treatment on Class II malocclusions. *Am J Orthod* 1979 Jan;75(1):20-26.
9. Yang EY, Kiyak HA. Orthodontic treatment timing: a survey of orthodontists. *Am J Orthod Dentofacial Orthop* 1998 Jan;113(1):96-103.
10. Ghafari J, Shofer FS, Jacobsson-Hunt U, Markowitz DL, Laster LL. Headgear versus function regulator in the early treatment of Class II, division 1 malocclusion: a randomized clinical trial. *Am J Orthod Dentofacial Orthop* 1998 Jan;113(1):51-61.
11. Bishara SE. Mandibular changes in persons with untreated and treated Class II division 1 malocclusion. *Am J Orthod Dentofacial Orthop* 1998 Jun;113(3):661-673.
12. Clark, WJ. The art of orthodontic. In: Clark WJ, editor. Twin block functional therapy application in dentofacial orthopaedics. London: Mosby-Wolfe Publication; 2002. p. 2-4.
13. Graber, TM.; Rakosi, T.; Petrovic, AG. Principles of functional appliances. Dentofacial orthopedics with functional appliances. St Louis (MO): Mosby; 1985.
14. Proffit, WR. Treatment of skeletal problems in children. In: Proffit WR, editor. Contemporary orthodontics. 4th ed. St. Louis (MO): Mosby, Elsevier Publication; 2007. p. 510-521.