

# Prevalence of Type of Frenal Attachment and Morphology of Frenum in Children, Chennai, Tamil Nadu

<sup>1</sup>S Linda Christabel, <sup>2</sup>Deepa Gurunathan

## ABSTRACT

**Background:** Labial frenum is a dynamic structure and is subject to variation in size, shape and position. The type of the maxillary labial frenal attachment and its morphology in children in Chennai has not been studied extensively. The purpose of this cross-sectional study is to examine the prevalence of the various types of maxillary frenal attachments and its morphology in children in Chennai.

**Materials and methods:** A study involving 931 Children between 3 and 12 years of age attending schools in Chennai were clinically examined for maxillary labial frenal attachment location and morphology under direct visual method. Parents were provided with informed consent. Demographic details including age and sex were recorded.

**Results:** Total number of children who were examined were 931. The most prevalent type of frenal attachment among all is gingival type followed by mucosal type of attachment. 49.5% were gingival type, 38.8% were mucosal type, 9.8% were papillary type and 1.9% were papillary penetrating type. The prevalence type had no gender difference but the age had significant association. The occurrence of papillary penetrating type decreases with age. The most prevalent morphological type is simple frenum 97% followed by simple frenum with nodule which is 2.6% and bifid labial frenum which is 0.4%.

**Conclusion:** The prevalent type among Chennai children is gingival type. The papillary penetrating type of frenal attachment decreases with age. The dentists should correlate the age of the child and type of frenal attachment and morphological variations during their clinical examination to avoid misdiagnosis and unnecessary treatment.

**Keywords:** Children, Maxillary frenal attachment, Morphology.

**How to cite this article:** Christabel SL, Gurunathan D. Prevalence of Type of Frenal Attachment and Morphology of Frenum in Children, Chennai, Tamil Nadu. World J Dent 2015;6(4):203-207.

**Source of support:** Nil

**Conflict of interest:** None

## INTRODUCTION

Labial frenum is a vertical band of oral mucosa that attaches the cheeks and lips to the alveolar mucosa of the

mandibular and maxillary arches, limiting the movement of the lips and cheeks.<sup>1,2</sup> Maxillary labial frenum has fibrous tissue which runs in antero-posterior direction and it ends by merging to the submucosal fibers of the lips.<sup>2,3</sup> The frenum has its origin from the remnant of central cells of vestibular lamina which predominantly has connective tissue and least amount of muscle fibers. The maxillary labial frenum is also said to be the posteruptive remnant of tectolabial bands.<sup>2,4</sup> Frenal attachments are at different levels at various stages of growth and development.<sup>5</sup> Placek et al classified different types of frenal attachments based on the anatomical location of the frenum in mucogingival junction, attached gingiva, interdental papilla and papilla extending to palate.<sup>6</sup> Papillary and papillary penetrating type of frenal attachments are said to be pathological beyond mixed dentition. Abnormal maxillary frenal attachments have several consequences. The abnormal frenal attachment acts as a hindrance for the tongue and the upper lip to form seal, thus making it difficult for the children in breast feeding. This which on negligence may lead to nutritional deficiency of the child.<sup>7</sup> As the pull of the abnormal frenal attachment is greater than normal, it produces constant force on the attached gingiva leading to localized gingival recession and requires orthodontic treatment later.<sup>8</sup> It may also lead to midline diastema which leads to flaring of the two upper central incisors due to the presence of thick bands of frenum which is not self correcting like ugly duckling stage and it requires minor surgical correction.<sup>9</sup> The orthodontic correction may also not be very efficient as it may lead to post-orthodontic relapse. In young children, the frenum is generally wide and thick which becomes thin and small during growth.<sup>10,11</sup> Thick labial frenum makes cleaning in that area difficult causing plaque accumulation which in turn may lead to caries in primary teeth.<sup>12</sup> The type of the maxillary labial frenal attachment and its morphology in children in Chennai has not been studied extensively. Maxillary labial frenum has shown various variations and anomalies. Two schools of thought exist as to the presence of nodules and frenal tags, i.e. it can be either familial or irregularity during development. The purpose of this cross-sectional study is to determine the prevalence of the type of maxillary frenal attachments and morphological variation in children in Chennai population.

<sup>1</sup>Postgraduate Student, <sup>2</sup>Reader

<sup>1</sup>Department of Conservative Dentistry and Endodontics, Ragas Dental College, Chennai, Tamil Nadu, India

<sup>2</sup>Department of Pedodontics, Saveetha Dental College, Chennai Tamil Nadu, India

**Corresponding Author:** Deepa Gurunathan, Reader, Department of Pedodontics, Saveetha Dental College, Chennai, Tamil Nadu India, e-mail: drgdeepa@yahoo.co.in

## MATERIALS AND METHODS

This cross-sectional study was undertaken using a convenience sample of children aged 3 to 12 years studying in schools in Chennai. Ethical approval for the study was obtained from Saveetha University Ethical Review Board. The study was conducted without violating the guidelines of the 'Declaration of Helsinki'. The parents of the participants were provided with written informed consent. The use of human subjects in this study has been reviewed and approved by the Institutional Review Board of Saveetha University (SRB/SDBDS14PE02). The children who were healthy with regular attendance participated for the clinical examination. Children with orofacial defects and those who were under medications for systemic diseases were excluded. Demographic information, such as age and gender were recorded. Children were divided into two groups according to age. Group 1: 3 to 6 years, group 2: 7 to 12 years. All examinations were performed by direct visual method. The children were examined in an upright position under natural day light using both hands to reflect the upper lips of the children. Sterilized mouth mirrors were used to view the palatal surface of the children for assessing any palatal attachment of the frenum. The type of frenal attachment was categorized based on classification by Placek et al.<sup>6</sup>

*Mucosal*—when the frenal fibers are attached up to mucogingival junction.

*Gingival*—when fibers are inserted within attached gingiva.

*Papillary*—when fibers are extending into inter dental papilla.

*Papilla penetrating*—when the frenal fibers cross the alveolar process and extend up to palatine papilla.

Morphological variations of frenal attachment were classified according to Sewerin include:<sup>13</sup>

- Simple frenum with a nodule
- Simple frenum with appendix
- Simple frenum with nichum
- Bifid labial frenum
- Persistent tectolabial frenum
- Double frenum
- Wider frenum.

### Statistical Data Analysis

Data collected were entered in SPSS version 16 and was subjected to statistical analysis. The association of frenum type with age, gender and dentition were calculated using Chi-square test as appropriate. Statistical significance was set at p-value <0.005.

## RESULTS

A total number of 931 children belonging to 3 to 12 years age group were examined of which 478 (51.3%) were male and 453 (48.6%) female children. Children were divided into two groups according to age. Among the types of frenal attachments gingival type of frenal attachment was the most common while papillary penetrating the least common (Graph 1). Table 1 shows the distribution of various types of frenal attachments among the two age groups. There was a significant difference in type of frenal attachment with age. Older children showed more of gingival type of attachment while papillary and papillary penetrating type of attachment is seen more commonly in younger children.

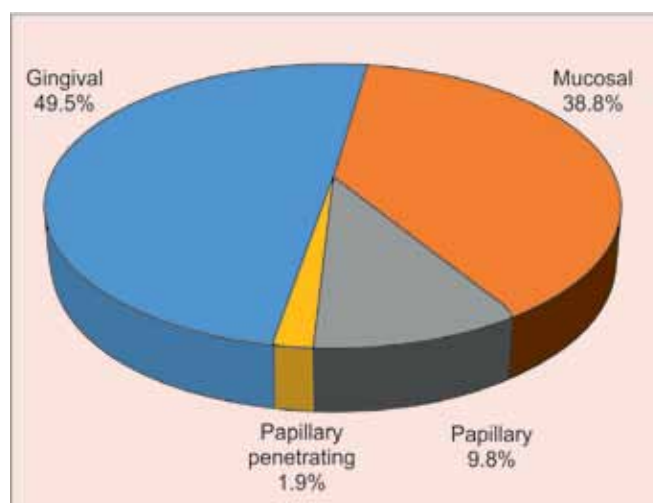
Among the gingival type of frenal attachment, 49.2% were males and 49.9% were females. Table 2 gives the various type of frenal attachment among male and female children. No significant difference in frenal attachment among genders.

An association between the type of dentition and frenal attachment was evaluated. Table 3 gives the distribution of frenal attachment across the types of dentition. Children with primary dentition were 192 (20.6%), children with mixed dentition were 732 (78.6%) and children with permanent dentition were 7 (0.8%).

The morphological variations of the maxillary frenum showed only three types of morphological frenal variation. Nine hundred and three (97.0%) children had simple frenum, 24 (2.6%) children had simple frenum with nodule and 4 (0.4%) children had bifid labial frenum (Table 4).

## DISCUSSION

Maxillary labial frenum is in a passive relationship with the maxillary alveolar process and its pattern of



Graph 1: Maxillary labial frenum attachment type distribution

**Table 1:** Prevalence of frenum type between age groups

Type	Age group					
	3–6 years		7–12 years		Total	
	N	%	N	%	N	%
Gingival	82	41.2	379	51.8	461	49.5
Mucosal	80	40.2	281	38.3	361	38.8
Papillary	30	15.1	61	8.4	91	9.8
Papillary penetrating	7	3.5	11	1.5	18	1.9
Total	199	100	732	100	931	100

Value = 35.812,  $p < 0.001$ **Table 2:** Prevalence of type of frenal attachment between male and female children

Type of frenal attachment	Male		Female		Total	
	N	%	N	%	N	%
Gingival	235	49.2	226	49.9	461	49.5
Mucosal	183	38.3	178	39.3	361	38.8
Papillary	49	10.3	42	9.3	91	9.8
Papillary penetrating	11	2.3	7	1.5	18	1.9
Total	478	100	453	100	931	100

Value = 1.002,  $p = 0.802$ **Table 3:** Prevalence of type of frenal attachment among types of dentitions

Type	Dentition							
	Primary		Mixed		Permanent		Total	
	N	%	N	%	N	%	N	%
Gingival	78	40.6	382	52.2	1	14.3	461	49.5
Mucosal	79	41.1	276	37.7	6	85.7	361	38.8
Papillary	27	14.1	64	8.7	0	0.0	91	9.8
Papillary penetrating	8	4.2	10	1.4	0	0.0	18	1.9
Total	192	100	732	100	7	100	931	100

Value = 21.745,  $p = 0.001$ **Table 4:** Prevalence of frenum type based on morphology

Type	Subtype																	Total	
	Simple frenum		Simple frenum with nodule		Bifid labial frenum		Simple frenum with appendix		Simple frenum with nichum		Tecto-labial frenum		Double frenum		Wider frenum				
N	%	N	%	N	%	N	%	N	%	N	%	N	%	N	%	N	%		
Gingival	455	98.7	5	1.1	1	0.2	0	0	0	0	0	0	0	0	0	461	100		
Mucosal	344	95.3	16	4.4	1	0.3	0	0	0	0	0	0	0	0	0	361	100		
Papillary	87	95.6	3	3.3	1	1.1	0	0	0	0	0	0	0	0	0	91	100		
Papillary penetrating	17	94.4	0	0.0	1	5.6	0	0	0	0	0	0	0	0	0	18	100		
Total	903	97	24	2.6	4	0.4	0	0	0	0	0	0	0	0	0	931	100		

development is dependent on alveolar growth.<sup>13,14</sup> In this present study, the prevalence of frenal attachments of 931 children in Chennai were examined. In this present study, we followed Placek et al<sup>6</sup> classification of frenal attachments as this classification is extensively used in children and adults in few other countries.<sup>15-17</sup> In the present study, the most common type of frenal attachment was found to be gingival. Similarly, Boutsi et al,<sup>15</sup> Addy et al,<sup>17</sup> Kaimenyi,<sup>18</sup> Upadaya,<sup>19</sup> and Bergese,<sup>20</sup> in their studies showed the most prevailing type of frenal attachment was gingival. However, Placek et al<sup>6</sup> and Janczuk and Banach<sup>16</sup> had found mucosal type of frenal attachment to be common in Czech and Polish teens respectively. This can also be compared with the present results as mucosal type of frenal attachment is more commonly seen in children above 11 years of age. Lindsey<sup>21</sup> reported papillary penetrating type to be the

prevalent type of frenal attachment in infants which is consistent with the present study. Whereas Boutsi et al<sup>15</sup> in their study, had mucosal to be the least common which could be attributed to the fact that the sample size above 13 years was very small. These variations in frenal attachment among studies can be attributed to the fact that the studies were conducted on population from various age groups. Hence, a direct comparison with other studies needs a careful observation.

Lindsey<sup>21</sup> and Popovich et al<sup>14</sup> also reported that the papillary penetrating type of frenal attachment decreased with increase in age which is in agreement with the present study. results. This could be attributed to the fact that the apical migration of frenum is due to the growth of alveolar process in coronal direction.<sup>14</sup> If papillary penetrating type of frenal attachments persists even after mixed dentition, it may lead to several consequences, such

as midline diastema<sup>9</sup> and dental caries.<sup>12</sup> The treatment of midline diastema is most commonly frenectomy<sup>22</sup> followed by orthodontic treatment to correct mal alignment.<sup>23</sup> Abnormal frenal attachment may also lead to speech abnormality,<sup>24</sup> poor oral hygiene maintenance.<sup>25</sup> However, children with speech abnormality were not observed in this study.

In this study, there is no significance association of frenal type with gender. Both males and females had more or less equal distribution which is in accordance with a study done in Greece.<sup>15</sup> In a study done in Kenyan population though the most prevalent type of frenal attachment was found to be gingival there was no association with gender or age.<sup>12,18,21</sup>

Though literature exists on prevalence of type of frenal attachments there is no association made with type of dentition.<sup>12,15,18,20,21</sup> In the present study, association of type of dentition and frenal attachment was also evaluated. The most prevalent type frenal attachment based on the location seen in primary dentition is mucosal, the mixed dentition is gingival and permanent dentition is mucosal.

To the best knowledge of the authors, this is the first study to evaluate the morphology of frenum along with type of frenal attachment. In this present study, the morphology was carried out based on the classification proposed by Sewerin et al<sup>13</sup> which is applicable both in children and adults.<sup>26</sup> In this present study, it is seen that simple frenum was the most prevalent type of frenum based on morphology in all the types of dentition which is concurrent with previous studies.<sup>13,27,28</sup> The eight types of frenum given by Sewerin et al<sup>13</sup> are the normal variants of the frenum based on morphology. In the above classification, persistent tectolabial frenum is often misdiagnosed as abnormal frenum. Diaz Piazen<sup>26</sup> had observed 24% of children less than 6 years of age had tectolabial frenum which was not observed in present study. Misdiagnosis of techtolabial frenum as a abnormal frenum leads to unnecessary surgical corrections. The tissue nodules and appendices are remnants and shown no pathological potential and do not warrant biopsy. Hence, lack of knowledge regarding the various types of frenal morphology resulted in unnecessary biopsies.<sup>26</sup>

In this present study, only apparently healthy children were chosen. Thereby no absence or abnormal morphology of frenum was observed. In contrary, abnormal frenal morphologies were associated with syndromes, such as Ehlers-Danlos syndrome, Ellis-van Creveld syndrome, and orofacial-digital syndrome and absence of frenum is seen in holoprosencephaly.<sup>29</sup>

The limitations in this study is its smaller sample size. A similar study should be conducted in a larger scale involving large number of samples and twins for

more reliable results. The association of frenal attachment with oral hygiene maintenance and dental caries were also not recorded. Hence, further studies involving the association of dental caries and oral hygiene maintenance should be considered.

Hence, it can be concluded that frenal attachment is at a more coronal level at a younger age and due to alveolar growth it assumes a gingival, and then mucosal type of attachment as age advances. Therefore, the dentists should correlate the age of the child and type of frenal attachment and morphological variations during their clinical examination to avoid misdiagnosis and unnecessary treatment.

## ACKNOWLEDGMENT

The authors wish to thank school authorities and children who participated in this study.

## REFERENCES

1. Parker DB. Surgical consideration of abnormal frena. In J Orthod Oral Surg 1937;23(11):1141-1148.
2. Dewel BF. The normal and the abnormal labial frenum: clinical differentiation. J Am Dent Assoc 1946;33:318-329.
3. Kotlow LA. Oral diagnosis of abnormal frenum attachments in neonates and infants: evaluation and treatment of maxillary frenum using the Erbium YAG Laser. J Pediatr Dent Care 2004c;10:11-14.
4. Henry SW, Levin MP, Tsaknis PJ. Histologic features of the superior labial frenum. J Periodontol 1976 Jan;47(1):25-28.
5. Ceremello PJ. The superior labial frenum and the midline diastema and their relation to growth and development of the oral structures. Am J Orthod 1953;39:120-139.
6. Placek M, Skach M, Mrklas L. Significance of the labial frenum attachment in periodontal disease in man—Part I: classification and epidemiology of the labial frenum attachment. J Periodontol 1974;45:891-894.
7. Wiessinger D, Miller M. Breastfeeding difficulties as a result of tight lingual and labial frena: a case report. J Hum Lact 1995 Dec;11(4):313-316.
8. Fowler EB, Breault LG. Early creeping attachment after frenectomy: a case report. Gen Dent 2000 Sep-Oct;48(5):591-593.
9. Edwards JG. The diastema, the frenum, the frenectomy: a clinical study. Am J Orthod 1977;71:489-508.
10. Curran M. Superior labial frenotomy. J Am Dent Assoc 1950;41:419-422.
11. Noyes HJ. The anatomy of the frenum labia in newborn infants. Angle Orthod 1935;1:3-8.
12. Kotlow LA. The influence of the maxillary frenum on the development and pattern of dental caries on anterior teeth in breastfeeding infants: prevention, diagnosis and treatment. J Human Lact 2001;26:304-308.
13. Sewerin I. Prevalence of variations and anomalies of the upper labial frenum. Acta Odontol Scand 1971;29(4):487-496.
14. Popovich F, Thompson GW, Main PA. The maxillary interincisal diastema and its relationship to the superior labial frenum and intermaxillary suture. Angle Orthod 1977;47:265-271.



15. Boutsis EA, Tatakis DN. Maxillary labial frenum attachment in children. *Int J Paed Dent* 2011;21(4):284-288.
16. Janczuk Z, Banach J. Prevalence of narrow zone of attached gingiva and improper attachment of labial frena in youths. *Comm Dent Oral Epidemiol* 1980;8:385-386.
17. Addy M, Dummer PM, Hunter ML, Kingdon A, Shaw WC. A study of the association of frenal attachment, lip coverage, and vestibular depth with plaque and gingivitis. *J Period* 1987;58:752-757.
18. Kaimenyi JT. Occurrence of midline diastema and frenum attachments amongst school children in Nairobi, Kenya. *Ind J Dent Res* 1998;9:67-71.
19. Upadhyay S, Upadaya NG. Attachment of maxillary labial frenum in Nepalese children. *Orthodontic J Nepal* 2012; 2(1):28-31.
20. Bergese F. Research on the development of the labial frenum in children of age 9-12 (in Italian). *Minerva Stomatol* 1966;15: 672-676.
21. Lindsey D. The upper mid-line space and its relation to the labial fraenum in children and in adults: a statistical evaluation. *Br Dent J* 1977;143:327-332.
22. Anubha N, Chaubey KK, Arora VK, Narula IS. Frenectomy combined with a laterally displaced pedicle graft. *Ind J Dent Sci* 2010;2:47-51.
23. Spilka CJ, Mathews PH. Surgical closure of diastema of central incisors. *Am J Orthod* 1979;76:443-447.
24. Miller PD Jr. Frenectomy combined with a laterally positioned pedicle graft; functional and aesthetic consideration. *J Periodontol* 1985;56:102-106.
25. Mirko P, Miroslav S, Lubor M. Significance of the labial frenum attachment in periodontal disease in man—Part I: classification and epidemiology of the labial frenum attachment. *J Periodontol* 1974;45:891-894.
26. Diaz-Piazen ME, Lagraverre MO, Villena R. Midline diastema and frenum morphology in primary dentition. *J Dent Child (Chic)* 2006;73:11-14.
27. Townsend JA, Brannon RB, Cheramie T, Hagan J. Prevalence and variations of the median maxillary labial frenum in children, adolescents and adults in a diverse population. *A General Dentistry* 2013;61(1):57-60.
28. Nagaveni NB, Umashankara KV. Morphology of maxillary labial frenum in primary, mixed, and permanent dentition of Indian children. *J Craniomaxillo Dis* 2014;1:5-10.
29. Priyanka M, Sruthi R, Ramakrishnan T, Emmadi P, Ambalavanan N. An overview of frenal attachments. *J Ind Soc Period* 2013;1:12-15.