

CASE REPORT

# Chronic Odontogenic Sinus Tracts associated with an Impacted Tooth: Report of Two Cases

<sup>1</sup>Ashwin DP, <sup>2</sup>Abhishek Mathur, <sup>3</sup>Anup Kumar G, <sup>4</sup>Lagna Gowda

<sup>1</sup>Reader, Department of Oral and Maxillofacial Surgery, VS Dental College and Hospital, Bengaluru, Karnataka, India

<sup>2</sup>Senior Resident, Department of Oral and Maxillofacial Surgery, Jhalawar Medical College, Jhalawar, Rajasthan, India

<sup>3</sup>Senior Lecturer, Department of Oral and Maxillofacial Surgery, NIMS Dental College, Thiruvananthapuram, Kerala, India

<sup>4</sup>Senior Lecturer, Department of Pedodontics, MR Ambedkar Dental College, Bengaluru, Karnataka, India

**Correspondence:** Ashwin DP, Reader, Department of Oral and Maxillofacial Surgery, VS Dental College and Hospital, Bengaluru Karnataka, India, e-mail: drashwindp3513@yahoo.com

**ABSTRACT**

Odontogenic sinus tracts in the face and neck region are relatively uncommon and may present a diagnostic problem. As specific dental symptoms usually are absent in these cases, patients generally visit physician first for the evaluation and treatment because of the absence of dental symptoms. These cutaneous sinus tracts are most commonly located on the chin, cheek or in the submandibular area and rarely in the nasal region. Diagnostic errors can result in multiple surgical excisions and biopsies, long-term antibiotic therapy and even radiation therapy or electrodesiccation.<sup>1</sup> The primary odontogenic disorder that results in such cutaneous lesions is typically a chronic periapical abscess or an impacted tooth or a root piece. We report two cases of extraoral sinus tracts, which were diagnosed as cutaneous sinus tracts of dental origin only after the failure of initial misdirected therapy.

**Keywords:** Odontogenic sinus, Cutaneous tracts.

**INTRODUCTION**

Odontogenic sinus tracts are the most common cause of a chronically draining, fixed, nodulocystic papule of the face and neck.<sup>1</sup> Cutaneous fistulas or sinus tracts of dental origin are well documented in the literature and respond extremely well to appropriate dental therapy. However, the majority of patients with odontogenic sinus tracts present to their physicians for treatment of an acute or chronic mass or a draining skin lesion. Since many of these patients have no dental symptoms, a high degree of suspicion is required to make the correct diagnosis. Because these lesions are often misdiagnosed, they are also ineffectively treated. Such patients may undergo multiple surgical excisions and biopsies and receive many courses of antibiotics, but all such measures fail and the sinus tract recurs.<sup>2</sup> We report two cases of extraoral sinus tracts, which were diagnosed as cutaneous sinus tracts of dental origin only after the failure of initial misdirected therapy.

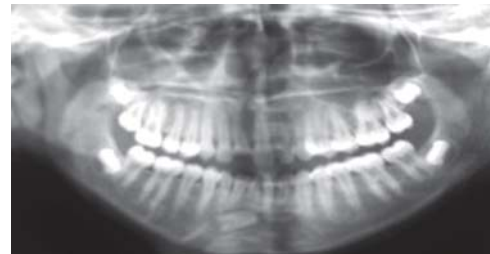

Fig. 1: Orthopantomogram (OPG)

**CASE REPORTS**

**Case 1**

A 14-year-old healthy boy with a complaint of discharging sinus on the lower right side of the face since 7 years reported to the department of oral and maxillofacial surgery, VS dental college and hospital. Patient gave a history of right mandibular fracture 7 years back and was operated for the same conservatively. Subsequently, patient had pus discharge, for which he consulted physician who diagnosed it as dermatological problem and treated with surgical drainage and curettage.

Examination revealed a sinus opening in the right submandibular region measuring about 1×1 cm with pus discharge. Intraorally 43 was found missing.

Radiographic examination revealed impacted 43.

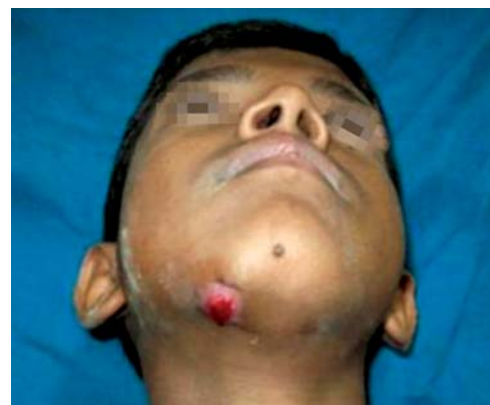

Fig. 2: Extraoral presentation (Case 1)

Patient was treated with excision of the extraoral sinus tract and surgical removal of 43 under general anesthesia. The postoperative course was uneventful. Histopathological report was consistent with the preoperative diagnosis. Further periodic

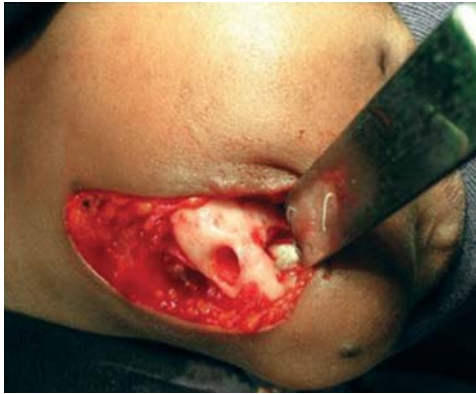


Fig. 3: Surgical exposure (Case 1)

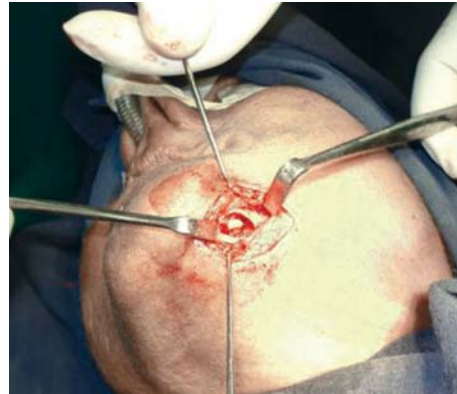

Fig. 6: Surgical exposure (Case 2)

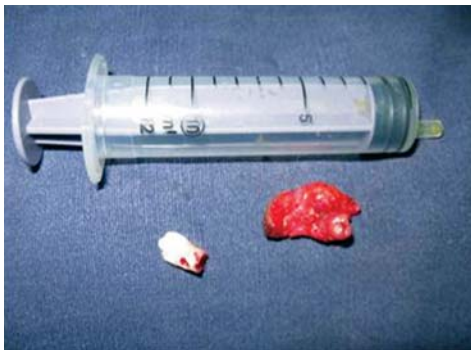

Fig. 4: Excised sinus tract with tooth

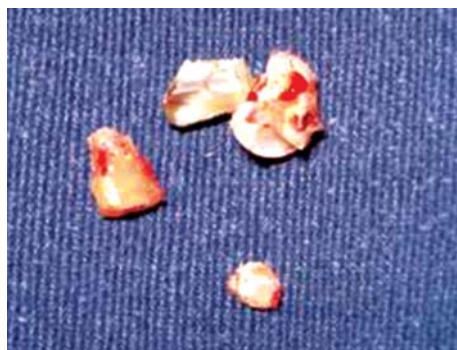

Fig. 7: Impacted tooth removed

follow-up was done at 1st, 2nd, 3rd weeks and 1month, which showed no signs of recurrence (Figs 1 to 4).

## Case 2

A 60-year-old female patient reported to our department with a complaint of pain in the front region of lower jaw and pus discharge from the same region since two years. Pain was dull, localized, intermittent and relieved on taking medications.

On examination, extraorally a diffused swelling was noted on left submandibular region about 2 × 2 cm with a sinus opening of about 5 mm associated with pus discharge. Intraoral

examination revealed sinus opening with pus discharge in the alveolar region of 35 and 36.

Radiographically OPG revealed impacted 35 with a diffused radiolucency in its periapical region.

Under the working diagnosis of impacted 35 with extraoral sinus tract opening, surgical removal of 35 with excision of sinus tract opening under general anesthesia was carried out along with a thorough debridement of the lesion done with curette. There were no complications related to the surgery.

The postoperative course was uneventful. Histopathological report was consistent with the preoperative diagnosis. Further periodic follow-up was done at 1st, 2nd, 3rd weeks and 1month, which showed no signs of recurrence (Figs 5 to 7).

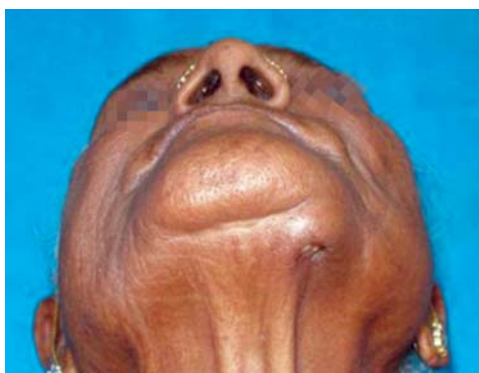


Fig. 5: Extraoral presentation (Case 2)

## DISCUSSION

The most common cause of chronic cutaneous sinus tract, in the face and neck, is a chronically draining dental infection.<sup>5</sup> The location of the sinus tract does not necessarily indicate the origin of the inflammatory exudates. Patients with the origin of the sinus tract incorrectly diagnosed undergo unnecessary surgical procedures and antibiotic therapy, as did the patients presented here. Both cases were finally managed successfully with appropriate surgical debridement at the source of the infection. Review of reports has shown that after misdiagnosis of the lesion, topical and surgical therapies are frequently attempted on cutaneous aspect of the lesion and no dental

treatment is provided. Recognition of the cutaneous lesion as sinus tract is the first important diagnostic step.<sup>4</sup>

Radiographic findings are very important for the diagnosis. A periapical radiograph of the involved area or OPG often reveals a carious tooth or retained roots or an impacted tooth along with the associated periapical lesion, which may be an abscess, a granuloma or a cyst. If the sinus tract is open, a lacrimal probe, diagnostic wire or gutta-percha cone can be used to trace its path from the cutaneous orifice to the point of origin. Treatment must be focused on elimination of the source of infection. After the dental origin of the cutaneous sinus has been eliminated or removed, cutaneous lesion usually resolved in 5 to 14 days.<sup>1</sup> If the sinus tract does not close after treatment, further evaluation, including microbial sampling and biopsy may be required. The most common alternative cause of a patent cutaneous fistula of dental origin is actinomycosis.<sup>3</sup> In addition, differential diagnosis of facial lesions should include sebaceous cysts, pyogenic granulomas, basal and squamous cell carcinomas, melanomas, infections such as syphilis and tuberculosis, epitheliomas, dermoid, branchial, thyroglossal cysts.<sup>1</sup>

## CONCLUSION

In our experience, the eradication of the dental source of infection invariably terminates suppuration, institutes healing and resolution of the cutaneous lesion. Communication between the dentist and the physician is suggested to provide timely recognition and treatment of rare cases.

## REFERENCES

1. Altug Uysal, Bahar Sezer, M Cemal Akay. Odontogenic sinus tracts. *Ege Tip Dergisi* 2004;43(2):121-25.
2. Jeong Uk Choi, Joon Kyoo Lee, Seung Eun Oh. Submandibular cutaneous draining sinus tract from mandibular osteomyelitis. *Korean J Otorhinolaryngol—Head Neck Surg* 2009;52:549-51.
3. SC Yeoh, S MacMohan, M Schifter. Chronic suppurative osteomyelitis of the mandible: Case report. *Australian Dental Journal* 2005;50(3):200-03.
4. Kaban LB. Draining skin lesions of dental origin: The path of spread of chronic odontogenic infection. *Plast Reconstr Surg* 1980;66(5):711-17.
5. Cioffi GA, Terezhalmay GT, Parlette HL. Cutaneous draining sinus tract: An odontogenic etiology. *J Am Acad Dermatol* 1986;14(1):94-100.