

Management of an Endodontic-periodontal Lesion caused by Iatrogenic Restoration

Yasser Alfawaz

ABSTRACT

Aim: This clinical case report demonstrates the successful management of a complex endodontic-periodontal iatrogenic lesion following a critical evaluation and decision-making process with interdisciplinary treatment strategies.

Background: Defective dental restorations can affect the periodontal and endodontic health of the teeth.

Case report: An endodontic-periodontal lesion that resulted from a faulty restoration in a 30-year-old male patient is reported. The management of the case is done through periodontal and endodontic treatment. The detailed method of managing of this type of cases is discussed.

Conclusion: In conclusion, the use of a systematic diagnosis process will help in the identification and treatment of iatrogenic endodontic-periodontal lesions.

Clinical significance: The correct management of endodontic-periodontal lesions can impede the loss of the involved teeth.

Keywords: Endodontic-periodontal lesion, Faulty restoration, Iatrogenic causes, Root canal treatment.

How to cite this article: Alfawaz Y. Management of an Endodontic-periodontal Lesion caused by Iatrogenic Restoration. World J Dent 2017;8(3):239-246.

Source of support: Nil

Conflict of interest: None

INTRODUCTION

Clinically, there is general agreement that the high incidence of tooth mortality might be a result of inadequate dental restorative treatments. This is based on the fact that defective restorations are factors contributing to deterioration of the periodontium and endodontium (i.e., they cause periodontal-endodontic disorders).^{1,2} Therefore, the final restoration has to be robust to maintain periodontal-endodontic health and this includes the consideration of restorative occlusion, the crown contour, and crown margin; moreover, the materials used in the restoration must be durable.³ The relationship between dental restorations and the health of the surrounding tissues

has been studied for many years. Most of these studies have focused on the negative response of endodontic-periodontal tissues to defective dental treatments.^{4,5}

The periodontium and endodontium develop with shared physiological channels, which may lead to the spread of pathological infections.⁶⁻⁸ The most common connection is the area of the apical foramen. Through the apical foramen, an infection of the endodontium can cause periapical periodontal lesions.⁹ Conversely, periodontitis with deep pockets reaching the tooth apex can result in an infection of the pulp tissues.^{10,11} However, connections between the periodontium and endodontium may also exist via the formation of nonphysiological pathways, known as iatrogenic endodontic-periodontal lesions.¹² In many instances, such iatrogenic dental incidents are unforeseeable complications of restorative treatments of endodontic-periodontal tissues if not performed properly. Fortunately, the improvement of such iatrogenic conditions can be achieved through early diagnosis and management.^{13,14} However, an endodontic-periodontal lesion can have an extended pathogenesis, which may progress to relatively complex and severe destruction of the surrounding tissues.

In such a clinical situation, a critical evaluation of the iatrogenic condition is essential to the decision-making process for a predictable treatment outcome. This is because the treatment process for iatrogenic endodontic-periodontal disorders is challenging and frequently viewed as an independent entity.¹⁴ Some periodontal lesions, which are closely related to endodontic lesions, can immediately resolve following pulp therapy alone. However, when there is complex communication between two lesions, appropriate treatment should be provided.^{15,16} Thus, prior to treatment, it is critical to recognize the interrelationships between existing endodontic-periodontal lesions to make sound clinical decisions.¹⁷ Although the improvement of an iatrogenic condition depends on the diagnosis and degree of endodontic-periodontal damage, the longevity of the tooth should be considered carefully. This mainly includes whether the tooth will be retained or extracted after treating the iatrogenic lesion.

CASE REPORT

A 30-year-old medically fit male patient presented to the restorative dentistry clinic complaining from mobile

Department of Restorative Dental Sciences, College of Dentistry
King Saud University, Riyadh, Kingdom of Saudi Arabia

Corresponding Author: Yasser Alfawaz, Department of Restorative Dental Sciences, College of Dentistry, King Saud University, Riyadh, Kingdom of Saudi Arabia, e-mail: yasseralfawaz@gmail.com

lower right mandibular tooth with uncomfortable bite in the same area. Patient also complained from unpleasant dark line around that mobile tooth in the same area. In a review of his dental history, the patient mentioned that he had crown treatment for two teeth in the lower right mandibular area 12 years ago. He said "since day one after treatment I felt uncomfortable bite in that side but I ignored that and got adapt to it with time. Recently, I had mobility on one of the crowned teeth. I went to several dentists, they all suggested extraction then implants as they prescribed it as non-restorable tooth. I want to keep my natural tooth if you can."

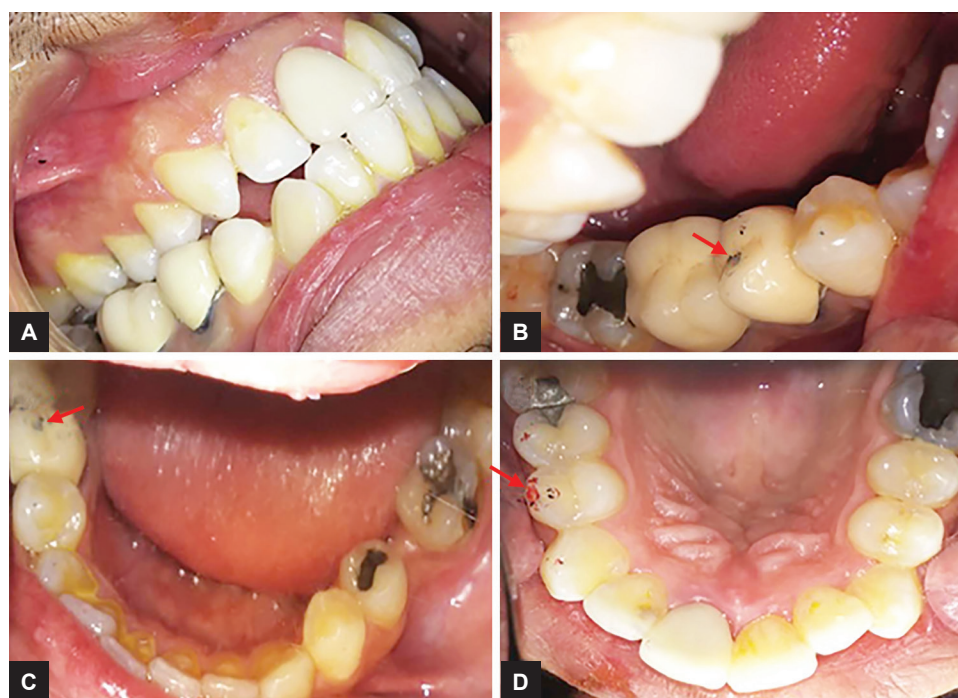
Clinical Examination

The oral examination revealed the following (Fig. 1). Fair oral hygiene, anterior edge-to-edge posterior cross-bite, malocclusion with maxillary and mandibular dental crowding, crowns on the lower right second mandibular premolar and first molar, and a localized occlusal high spot on the lower right second mandibular premolar and corresponding upper right first maxillary premolar. Further, grade II mobility of the lower right second mandibular premolar was noted, as were 4-mm periodontal pockets around the tooth. The radiographic examination suggested the following (Fig. 2). Porcelain fused to metal (PFM) crowns with pins was retained on the amalgam core on both the lower right second mandibular premolar and first molar. No carious lesion was found on either crown. Both crowns underwent root

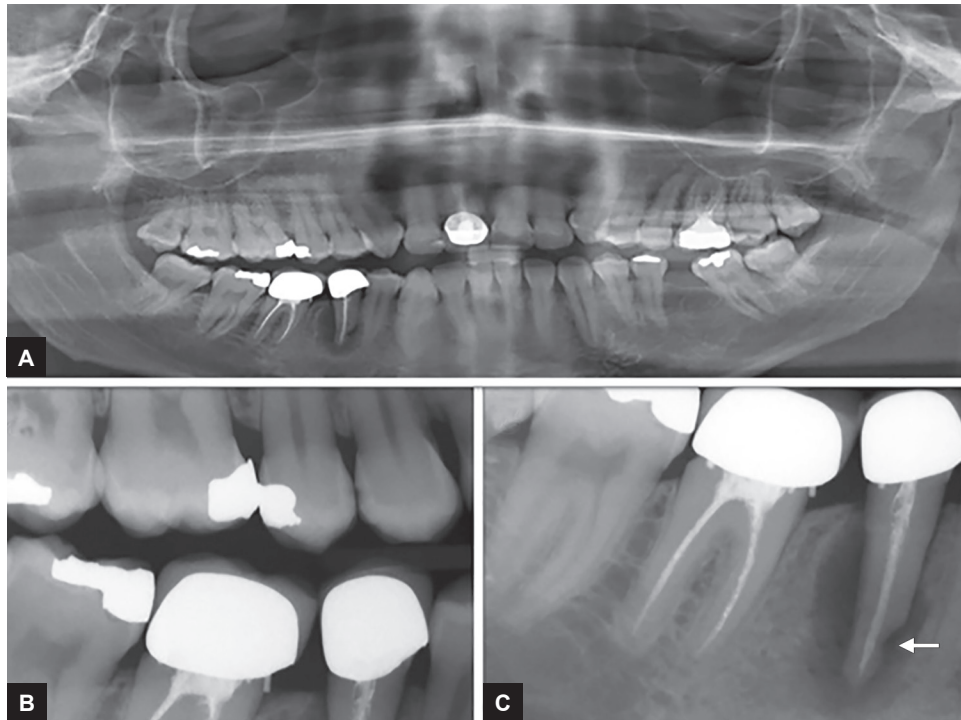
canal treatment previously. A periapical radiograph of the second premolar showed a large periapical lesion associated with bone resorption and localized root resorption. Moreover, a modified clinical and radiographic examination decision-making form was used to identify the characteristics of the lesion (Table 1). Most of the clinical and radiographic findings were in the iatrogenic condition column.

Treatment Options

Although the patient was not interested in implant treatment, oral surgery and endodontic consultations were performed to finalize the treatment options to address his dental needs and concerns. The findings of clinical and radiographic examinations were presented and discussed with the patient, and treatment options, with potential risks and complications of each option, were explained. Two treatment options were presented: Option 1 was extraction of lower right second mandibular premolar and then implant to be done, root canal retreatment then crown for the lower right first molar; option 2 was root canal retreatment for lower right second mandibular premolar, followed by period tissue healing response assessment; if healing occurs crown should be done, if not option 1 treatment will be the only choice, the lower right first molar has only the option presented in option 1. After thorough discussion, the patient opted to do option 2 except he did not want any treatment to be done to lower right first molar. His concern was to get treated only for



Figs 1A to D: Preoperative images: (A) Right lateral view; (B and C) Occlusal view showing an occlusal high spot on tooth 45 (red arrows); and (D) An occlusal view of the opposing dentition showing an occlusal high spot on tooth 14 (red arrow).



Figs 2A to C: Preoperative radiographs: (A) Orthopantomogram; (B) Bitewing radiograph; and (C) Periapical radiograph showing a large periradicular radiolucency and localized root resorption (white arrow) related to tooth 45

Table 1: Diagnosis of the exact lesion*

	<i>Endodontic condition</i>	<i>Periodontal condition</i>	<i>Iatrogenic condition</i>
Visual examination	<input type="checkbox"/> Presence of sinus tract <input type="checkbox"/> Presence of decay <input type="checkbox"/> Large restoration <input type="checkbox"/> Fractured restoration or tooth <input type="checkbox"/> Erosions <input type="checkbox"/> Abrasions <input type="checkbox"/> Cracks <input type="checkbox"/> Discolorations <input checked="" type="checkbox"/> Poor RCT	<input checked="" type="checkbox"/> Gingivitis, periodontitis <input type="checkbox"/> Gingival recession <input type="checkbox"/> Accumulation of plaque <input type="checkbox"/> Subgingival calculus <input type="checkbox"/> Intact teeth <input type="checkbox"/> Periodontal abscess	<input checked="" type="checkbox"/> Gingivitis, periodontitis <input type="checkbox"/> Swelling around tooth <input type="checkbox"/> Presence of pus, exudate <input checked="" type="checkbox"/> Defective restoration <input checked="" type="checkbox"/> Poor RCT
Pain	<input type="checkbox"/> Sharp	<input type="checkbox"/> Dull ache <input type="checkbox"/> Sharp only in acute condition	<input type="checkbox"/> Dull ache <input type="checkbox"/> Sharp only in acute condition
Palpation	<input type="checkbox"/> Pain on palpation	<input type="checkbox"/> Pain on palpation	<input type="checkbox"/> Pain on palpation
Percussion	<input type="checkbox"/> Tender on percussion	<input type="checkbox"/> Tender on percussion	<input type="checkbox"/> Tender on percussion
Mobility	<input type="checkbox"/> Fractured roots and traumatized tooth present high mobility	<input type="checkbox"/> Localized and generalized mobility	<input checked="" type="checkbox"/> High mobility related to the involved tooth
Pulp vitality	<input type="checkbox"/> Irreversible pulpitis <input type="checkbox"/> Necrotic pulp	<input type="checkbox"/> The pulp is vital	<input type="checkbox"/> Nonvital pulp
Sinus tracing	<input type="checkbox"/> A radiograph with gutta percha points to apex	<input type="checkbox"/> Sinus tract mainly at the lateral aspect of the root	<input checked="" type="checkbox"/> Difficult to trace out the origin of the lesion radiographically
Radiographs	<input type="checkbox"/> Deep carious <input checked="" type="checkbox"/> Defective restorations <input checked="" type="checkbox"/> Previous poor RCT <input type="checkbox"/> Possible mishaps <input type="checkbox"/> Root fractures <input type="checkbox"/> Periapical radiolucency	<input type="checkbox"/> Vertical bone loss <input type="checkbox"/> Bone loss wider coronally <input checked="" type="checkbox"/> Previous poor RCT <input type="checkbox"/> Possible mishaps <input checked="" type="checkbox"/> Root resorption	<input checked="" type="checkbox"/> Periradicular bone loss <input checked="" type="checkbox"/> Defective restorations
Cracked tooth test	<input type="checkbox"/> Painful response with chewing	<input type="checkbox"/> No symptoms	<input type="checkbox"/> Painful response with chewing

*Modified from Rotstein and Simon¹²; RCT: Root canal treatment

☒ These marks determine findings detected in the present case, most of the finding was in the iatrogenic condition columns

the mobile lower right second premolar. However, he was informed that the lower right first molar would need to be monitored for early diagnosis of tissue lesions or caries.

Root Canal Treatment

The patient was referred to an endodontist after the initial consultation appointment. Thorough clinical and radiographic examination revealed a diagnosis of previously treated tooth #45 with symptomatic apical periodontitis. Nonsurgical root canal retreatment was initiated after removing the old PFM crown. The access cavity preparation was performed through the old pin and the core build-up material. Gutta percha was removed and the canal was cleaned and shaped up to size 45 K3 files with 0.04 taper. Canal was irrigated with 10 mL of 5.25% sodium hypochlorite and 1 mL 17% ethylenediaminetetraacetic acid (EDTA). The canal was dried with paper points and filled with calcium hydroxide, $\text{Ca}(\text{OH})_2$ (Fig. 3A). The access cavity was sealed with cavit. After 2 weeks, the patient presented to continue root canal retreatment. He reported no more pain and that he felt much better. The tooth was reaccessed and $\text{Ca}(\text{OH})_2$ was removed with size 45 K3 file and irrigation with 5.25% sodium hypochlorite and 17% EDTA. Obturation was completed using warm vertical compaction of gutta percha with AH 26[®] sealer. Access cavity was sealed with cavit and glass ionomer cement, and tooth was kept out of occlusion (Fig. 3B).

Fiber Post and Core Buildup

Patient was seen after 4 months post-Endo treatment to evaluate tissue healing and tooth mobility before final crown treatment. Patient was asymptomatic with no pain on biting. Preapical radiograph shows significant reduction of the size of the periapical radiolucency. Clinically, no mobility or periodontal pocket was detected (Fig. 3C).

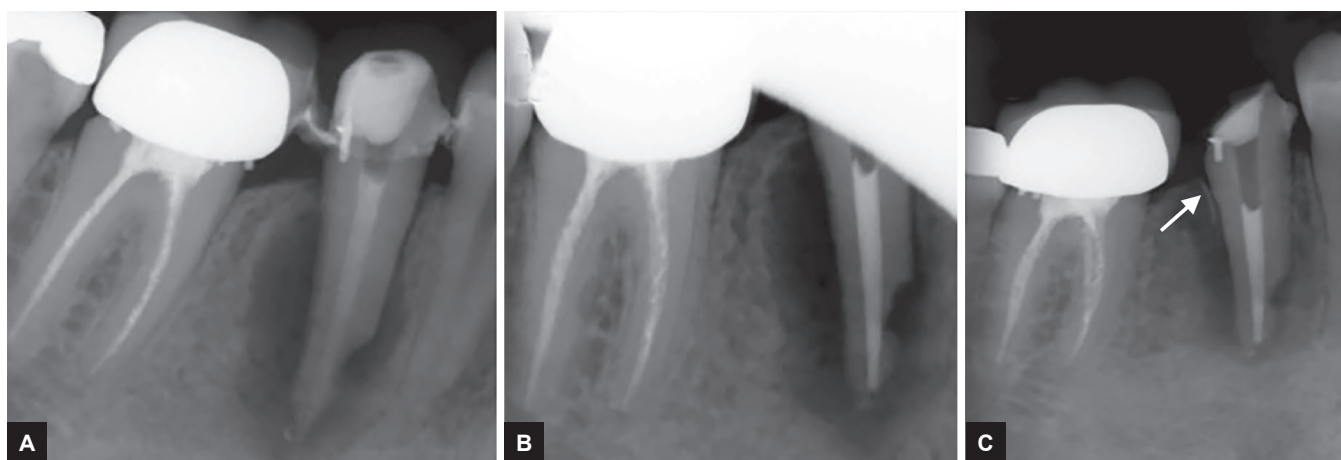
Temporary restoration was removed and the canal wall was enlarged with low-speed post drills provided by the manufacturer, in order to create the post space. Fiber post cementation using RelyX Unicem (3M ESPE, St. Paul, MN, USA) self-adhesive resin cement luted the posts and the canal following the manufacturer's instructions. Composite core buildup was done using MultiCore Flow (Ivoclar Vivadent, Schaan, Liechtenstein) following the manufacturer's instructions (Fig. 4A). Patient was rescheduled for crown preparation and final impression.

Crown Preparation and Final Impression

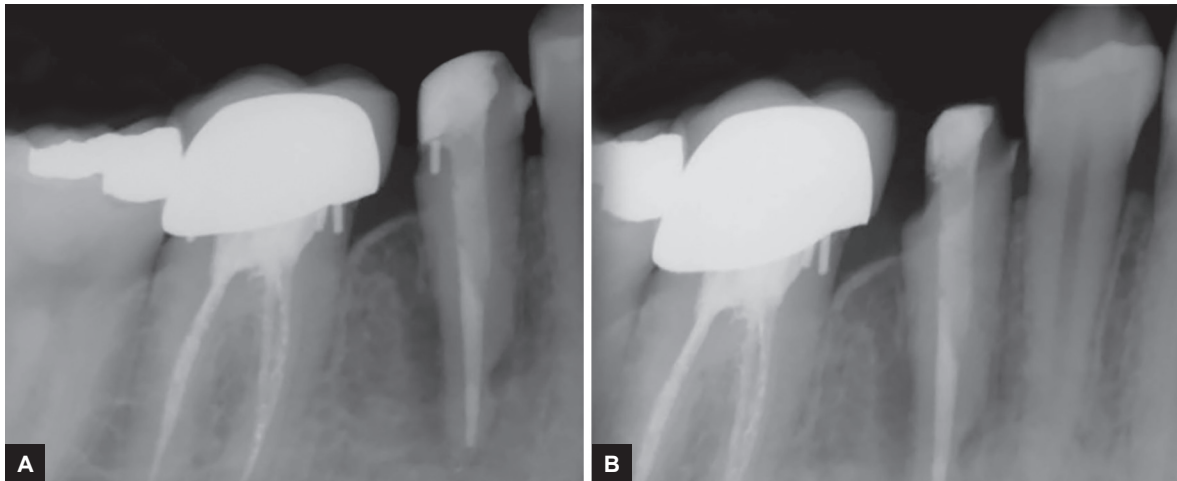
Crown preparation was done and the distal finish line was dropped to remove the old metal pin in that area (Fig. 4B). The preparation was finalized and the final impression was taken with President Plus polyvinyl siloxane impression material (Coltène Whaledent AG, Altstätten, Switzerland). After discussion with the patient, A2 Vitapan classic shade was selected as the final crown shade (VITA Zahnfabrik H. Rauter GmbH & Co. KG, Bad Säckingen, Germany). Provisional crown was fabricated with self-cure provisional material (Systemp.c&b II; Ivoclar Vivadent AG). TempBond NE (Kerr, Romulus, Michigan, USA) – a noneugenol temporary cement – was used to cement the provisional crown. Impression was sent to the lab to fabricate the final crown with A2 IPS e.max Press lithium disilicate glass-ceramic system (Ivoclar Vivadent AG).

Cementation and Crown Delivery

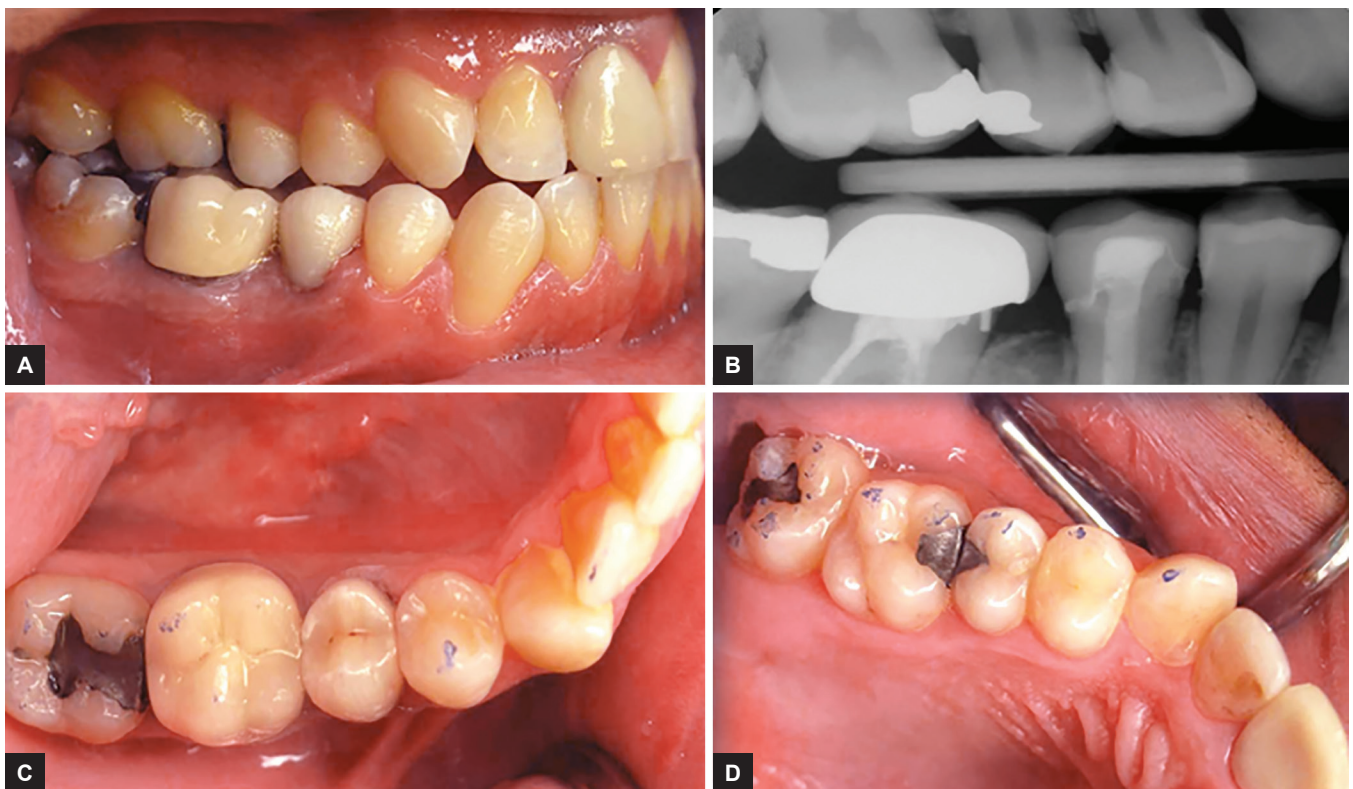
Before the patient arrived for the cementation visit, the crown was tried-in on the working cast to evaluate the contours, marginal fit, proximal contacts, and axial contours. The provisional crown was removed, and tooth was



Figs 3A to C: Periapical radiographs: (A) Periapical radiograph showing the root canal filled with calcium hydroxide after cleaning and shaping; (B) Periapical radiograph obtained immediately after root canal treatment; and (C) Periapical radiograph obtained 4 months after root canal treatment (the white arrow shows alveolar crest regeneration)



Figs 4A and B: Periapical radiographs: (A) Obtained after fiber post cementation and resin core build-up; and (B) Obtained after the final crown preparation; the distal finish line was dropped to remove the old metal pin

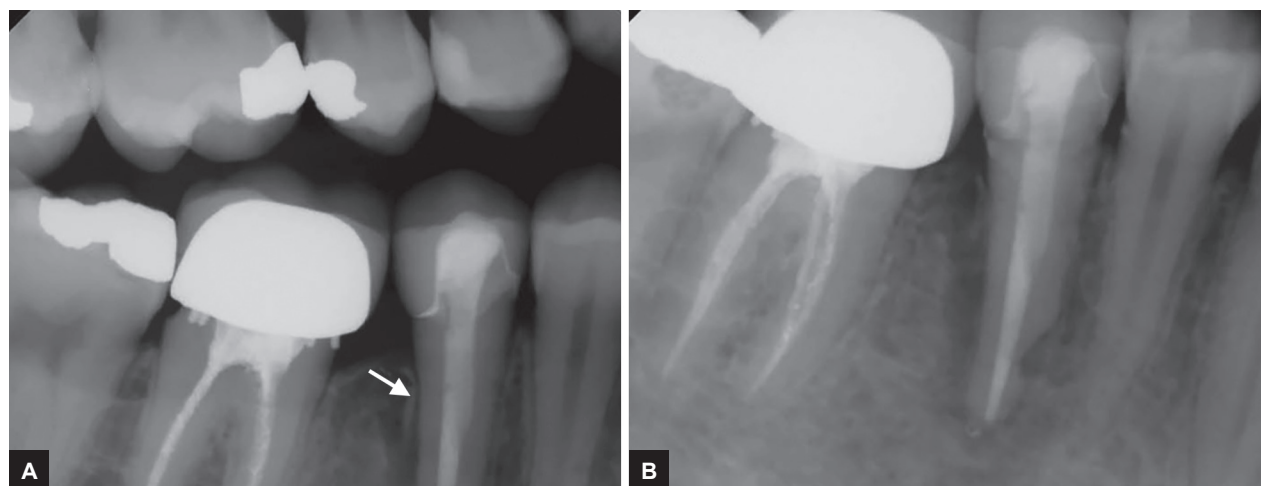


Figs 5A to D: Postoperative images and a radiograph: (A) Right lateral view; (B) Bitewing radiograph; and (C and D) Occlusal views of the lower right side and opposing upper right side

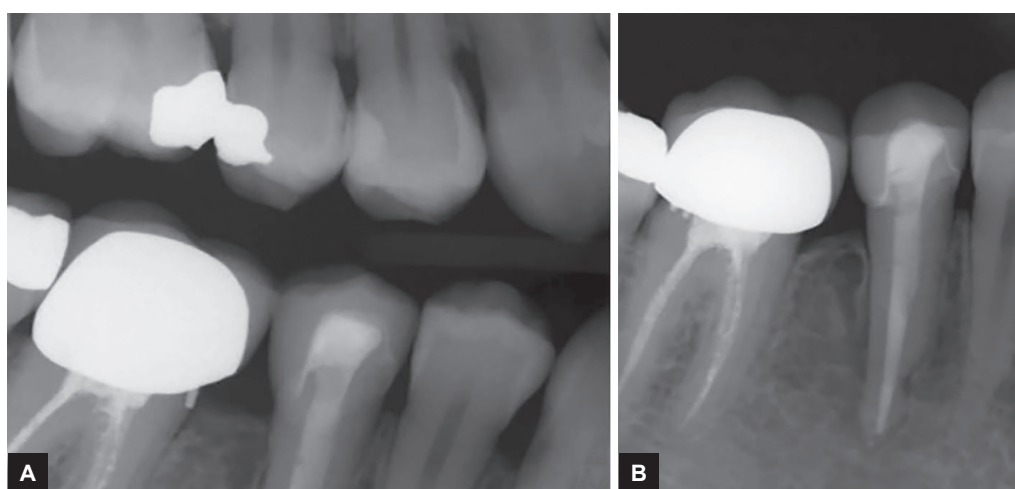
cleaned with a soft rubber cup and fine pumice. After careful evaluation and patient's approval of the crown, cementation was done using RelyX Unicem (3M-ESPE, St. Paul, MN, USA) self-adhesive resin cement following the manufacturer's instructions. The excess luting cement was gently removed, and occlusion was examined in centric and eccentric movements by means of ultrathin articulating paper (Henry Schein, Melville, New York, USA) (Fig. 5).

One-year and Two-year Follow-up Appointments

Patient came for the 1-year follow-up visit; periapical and bitewing radiographs were taken (Fig. 6). The radiographs show positive lesion healing and good bone regeneration. Post 2 years, radiographs showed (Fig. 7) nearly complete lesion healing and bone regeneration with clear normal appearance of the alveolar crests. Patient reported asymptomatic tooth at both visits.



Figs 6A and B: One-year follow-up radiographs: (A) Bitewing radiograph; and (B) Periapical radiograph (white arrow shows alveolar crest regeneration)



Figs 7A and B: Two-year follow-up radiographs: (A) Bitewing radiograph; and (B) Periapical radiograph

DISCUSSION

In the above case, a dental restoration resulted in an iatrogenic endodontic-periodontal lesion due to inappropriate performance of a restorative treatment plan. In sequence, a careful clinical and radiographic examination was performed to identify problems and develop an accurate decision-making process to treat the iatrogenic endodontic-periodontal lesion in the present case. As a result, the diagnostic process and interdisciplinary treatment approach produced an optimal clinical outcome that has been maintained for 2 years.

The pulp and periodontium have anatomic and functional interrelationships as first described by Simring and Goldberg.¹⁸ However, treating a complex endodontic-periodontal lesion is still one of the most common challenges in today's clinical practice. The simultaneous existence of endodontium and periodontium tissue destruction can complicate the diagnosis and subsequently affect the prognosis of the involved teeth.¹⁶

As a result of the unpredictable prognosis, extractions are often favored over retreatment procedures because of underestimations of the treatment success of truly iatrogenic endodontic-periodontal lesions. This highlights the importance of following a critical diagnostic strategy to ensure a correct treatment plan, particularly for patients with an iatrogenic endodontic-periodontal condition. Indeed, several teeth associated with endodontic-periodontal lesions that are properly treated were reported to have successful outcomes. Aksel and Serper¹⁹ published a case series of treatment strategies associated with different kinds of endodontic-periodontal lesions. They showed that more predictable outcomes could be obtained with an optimal diagnosis as well as proper treatment sequences and intervals.

Endodontic treatment is highly predictable when appropriately performed.^{20,21} However, effective endodontic therapy might not always repair severe bone loss due to periodontitis.^{1,22} In the present case, adequate endodontic therapy resulted in substantial healing of both the

endodontic and periodontal components. Following endodontic treatment, the periodontal lesion was reduced to a large extent in the radiographic evaluation after 2 years with positive changes in the characteristic appearances of the alveolar crests. The alveolar crests appeared normal and were observed to be 1 to 2 mm below the cemento-enamel junction. For endodontic retreatment, calcium hydroxide was used as an intracanal medicament. The use of calcium hydroxide paste was indicated because of its antibacterial, anti-inflammatory, and proteolytic properties.¹¹ In addition, calcium hydroxide inhibits root resorption and enhances endodontic-periodontal repair.²⁰ Accordingly, successful outcomes were obtained after proper disinfection and sealing of the endodontic system in clinical cases presented previously.²³ In addition, Kim et al²⁴ performed a prospective study to evaluate the treatment outcomes of cases with lesions of combined endodontic-periodontal origin. They recommended that endodontic-periodontal involvement could be treated initially with endodontic therapy and then the condition could be reevaluated after 23 months. In fact, the optimal interval between endodontic treatment and evaluation of the periodontal condition is somewhat controversial in the literature.^{6,9,25} However, the periodontal assessment should depend on the severity of periodontal involvement and response to endodontic therapy. Although the results of case reports should be confirmed by future clinical studies, it must be emphasized that a correct diagnosis and treatment are essential prerequisites for successful long-term clinical results.

CONCLUSION

The decision-making process used in this case report can guide the clinician in managing the treatment of iatrogenic endodontic-periodontal lesions. In addition, long-term clinical outcomes are more predictable when there are optimal diagnostic processes, treatment sequences, and intervals. Therefore, the immediate and correct management of endodontic-periodontal lesions can impede the loss of the involved teeth.

ACKNOWLEDGMENTS

Author would like to thank Dr Hamdan S. Alghamdi, Assistant Professor at the Periodontics and Community Dentistry Department, King Saud University Dental College, Riyadh, Kingdom of Saudi Arabia, and Dr Riyadh I. Althumairy, Assistant Professor at the Restorative Dental Science Department (Division of Endodontic Dentistry), King Saud University Dental College, Riyadh, Kingdom of Saudi Arabia, for their help in the consultation and management of the present case.

REFERENCES

- Harrington GW, Steiner DR, Ammons WF. The periodontal-endodontic controversy. *Periodontol* 2000 2002;30:123-130.
- Holm-Pedersen P, Lang NP, Müller F. What are the longevities of teeth and oral implants? *Clin Oral Implants Res* 2007 Jun;18 (Suppl 3):15-19.
- Goldberg PV, Higginbottom FL, Wilson TG. Periodontal considerations in restorative and implant therapy. *Periodontol* 2000 2001;25:100-109.
- Gracis S, Fradeani M, Celletti R, Bracchetti G. Biological integration of aesthetic restorations: factors influencing appearance and long-term success. *Periodontol* 2000 2001;27: 29-44.
- Kois JC. The restorative-periodontal interface: biological parameters. *Periodontol* 2000 1996 Jun;11:29-38.
- Schacher B, Haueisen H, Ratka-Krüger P. The chicken or the egg? Periodontal-endodontic lesions. *Periodontal Practice Today* 2007;4(1):15-21.
- Simon JH, Glick DH, Frank AL. The relationship of endodontic-periodontic lesions. *J Periodontol* 1972 Apr;43(4): 202-208.
- Zehnder M, Gold SI, Hasselgren G. Pathologic interactions in pulpal and periodontal tissues. *J Clin Periodontol* 2002 Aug;29(8):663-671.
- Sjögren U, Figdor D, Persson S, Sundqvist G. Influence of infection at the time of root filling on the outcome of endodontic treatment of teeth with apical periodontitis. *Int Endod J* 1997 Sep;30(5):297-306.
- Bergenholtz G, Nyman S. Endodontic complications following periodontal and prosthetic treatment of patients with advanced periodontal disease. *J Periodontol* 1984 Feb;55(2):63-68.
- Nair PN. Pathogenesis of apical periodontitis and the causes of endodontic failures. *Crit Rev Oral Biol Med* 2004 Nov;15(6):348-381.
- Rotstein I, Simon JH. Diagnosis, prognosis and decision-making in the treatment of combined periodontal-endodontic lesions. *Periodontol* 2000 2004;34:165-203.
- Tamse A. Iatrogenic vertical root fractures in endodontically treated teeth. *Endod Dent Traumatol* 1988 Oct;4(5): 190-196.
- Rotstein I, Simon JH. The endo perio lesion: a critical appraisal of the disease condition. *Endodontic Topics* 2006 Mar;13(1):34-56.
- Ahmed H. Different perspectives in understanding the pulp and periodontal intercommunications with a new proposed classification for endo-perio lesions. *ENDO (Lond Engl)* 2012;6(2):87-104.
- Singh P. Endo-perio dilemma: a brief review. *Dent Res J (Isfahan)* 2011 Mar;8(1):39-47.
- Gorni FG, Gagliani MM. The outcome of endodontic retreatment: a 2-yr follow-up. *J Endod* 2004 Jan;30(1):1-4.
- Simring M, Goldberg M. The pulpal pocket approach: retrograde periodontitis. *J Periodontol* 1964 Jan;35(1):22-48.
- Aksel H, Serper A. A case series associated with different kinds of endo-perio lesions. *J Clin Exp Dent* 2014 Feb;6(1): e91-e95.
- John V, Warner NA, Blanchard SB. Periodontal-endodontic interdisciplinary treatment – a case report. *Compend Contin Educ Dent* 2004 Aug;25(8):601-602, 604-606, 608.

21. Kerezoudis NP, Siskos GJ, Tsatsas V. Bilateral buccal radicular groove in maxillary incisors: case report. *Int Endod J* 2003 Dec;36(12):898-906.
22. Zubery Y, Machtei EE. Periodontic-endodontic treatment of severe alveolar lesions. *Gen Dent* 1993 Jan-Feb;41(1):56-59.
23. Jivoinovici R, Suci I, Dimitriu B, Perlea P, Bartok R, Malita M, Ionescu C. Endo-periodontal lesion – endodontic approach. *J Med Life* 2014 Oct-Dec;7(4):542-544.
24. Kim E, Song JS, Jung IY, Lee SJ, Kim S. Prospective clinical study evaluating endodontic microsurgery outcomes for cases with lesions of endodontic origin compared with cases with lesions of combined periodontal-endodontic origin. *J Endod* 2008 May;34(5):546-551.
25. Kambale S, Aspalil N, Munavalli A, Ajgaonkar N, Babannavar R. A sequential approach in treatment of endo-perio lesion a case report. *J Clin Diagn Res* 2014 Aug;8(8):Zd22-Zd24.